



HAL
open science

Rescue one-stage hybrid perventricular and percutaneous device closure of multiple muscular ventricular septal defects using the new multifunctional occluder

Paul Padovani, Mohamedou Ly, Alban-Elouen Baruteau

► **To cite this version:**

Paul Padovani, Mohamedou Ly, Alban-Elouen Baruteau. Rescue one-stage hybrid perventricular and percutaneous device closure of multiple muscular ventricular septal defects using the new multifunctional occluder. *Annals of Pediatric Cardiology*, 2024, 17 (2), pp.146 - 148. 10.4103/apc.apc_16_24 . hal-04820148

HAL Id: hal-04820148

<https://nantes-universite.hal.science/hal-04820148v1>

Submitted on 5 Dec 2024

HAL is a multi-disciplinary open access archive for the deposit and dissemination of scientific research documents, whether they are published or not. The documents may come from teaching and research institutions in France or abroad, or from public or private research centers.

L'archive ouverte pluridisciplinaire **HAL**, est destinée au dépôt et à la diffusion de documents scientifiques de niveau recherche, publiés ou non, émanant des établissements d'enseignement et de recherche français ou étrangers, des laboratoires publics ou privés.



Distributed under a Creative Commons Attribution - NonCommercial - NoDerivatives 4.0 International License

Rescue one-stage hybrid perventricular and percutaneous device closure of multiple muscular ventricular septal defects using the new multifunctional occluder

Paul Padovani¹, Mohamedou Ly¹, Alban-Elouen Baruteau^{1,2,3,4}

¹Department of Pediatric Cardiology and Pediatric Cardiac Surgery, CHU Nantes, Nantes University, FHU PRECICARE, Nantes, France, ²Nantes University, CHU Nantes, INSERM, CIC FEA, Nantes, France, ³Nantes University, CHU Nantes, CNRS, INSERM, l'institut du Thorax, Nantes, France, ⁴Nantes University, INRAE, UMR, PhAN, Nantes, France

ABSTRACT

Data on the safety and efficiency of perventricular device closure of complex ventricular septal defects (VSDs) are scarce. We report successful one-stage combined hybrid perventricular and percutaneous closure of the muscular VSDs in a critically ill 4-kg infant, using the new multifunctional occluder.

Keywords: Cardiac catheterization, congenital heart disease, hybrid operating room, hybrid procedure

INTRODUCTION

Data regarding the safety and efficiency of perventricular device closure of complex postoperative muscular ventricular septal defects (VSDs) in low-body-weight infants using the new multifunctional occluder (MFO) are limited. Herein, we present an infant with multiple residual VSDs, which were closed by combined hybrid perventricular and transcatheter closure using an MFO device. Our case report adds unique data to the current body of knowledge.

CASE REPORT

A 4-kg, 3-month-old infant operated on for complete atrioventricular septal defect and muscular VSD had a complicated postoperative course with hemodynamic instability requiring central venoarterial extracorporeal membrane oxygenation (ECMO) support because of a 6-mm residual trabecular VSD and a 5-mm residual apical VSD [Figure 1]. Hybrid VSD closure was planned in this infant with an open chest and low body weight.

Through a perventricular 5-F introducer, a 4-F Judkins Right catheter on a 0.035" guidewire crossed the apical VSD, and a 5-F SteerEase delivery sheath (Lifetech, Shenzhen, China) was advanced over the wire, allowing for the deployment of an 8/6-mm MFO device (Lifetech, Shenzhen, China) [Figure 2]. The right ventricular disc of the device appeared elongated along the right ventricular apical region, indicating the device's conformability to the restricting cardiac structures. As the mid-muscular VSD could not be crossed from the puncture site in the right ventricular free wall, a 4-F sheath was inserted in the femoral artery, and the defect was crossed from the left ventricle. A 5-F SteerEase sheath was advanced into the pulmonary artery, and a 7/5-mm MFO was deployed [Figures 3 and 4]. ECMO weaning was performed on the same day.

After 2 years of follow-up, the patient was asymptomatic without residual VSD. Despite successful management,

This is an open access journal, and articles are distributed under the terms of the Creative Commons Attribution-NonCommercial-ShareAlike 4.0 License, which allows others to remix, tweak, and build upon the work non-commercially, as long as appropriate credit is given and the new creations are licensed under the identical terms.

For reprints contact: WKHLRPMedknow_reprints@wolterskluwer.com

How to cite this article: Padovani P, Ly M, Baruteau AE. Rescue one-stage hybrid perventricular and percutaneous device closure of multiple muscular ventricular septal defects using the new multifunctional occluder. *Ann Pediatr Card* 2024;17:146-8.

Access this article online

Quick Response Code:



Website:

<https://journals.lww.com/aopc>

DOI:

10.4103/apc.apc_16_24

Address for correspondence: Prof. Alban-Elouen Baruteau, Department of Pediatric Cardiology and Pediatric Cardiac Surgery, CHU Nantes, Nantes University, FHU PRECICARE, Nantes, France.

E-mail: albanelouen.baruteau@chu-nantes.fr

Submitted: 30-Jan-2024

Revised: 22-Mar-2024

Accepted: 04-Apr-2024

Published: 20-Jul-2024

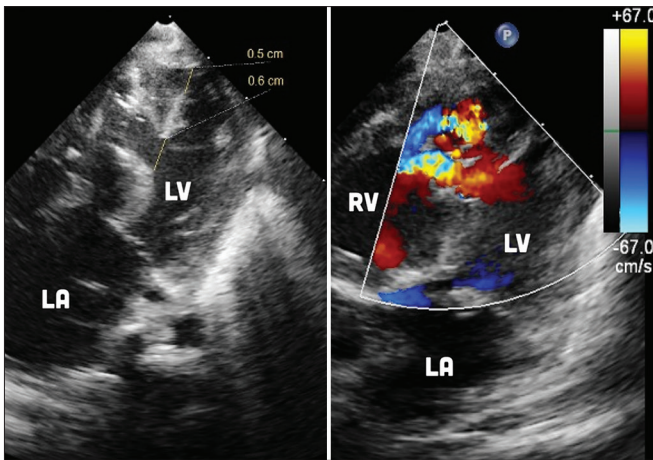


Figure 1: Postoperative echocardiogram shows significant left-to-right shunt through large, surgically challenging residual ventricular septal defects. LA: Left atrium, LV: Left ventricle, RV: Right ventricle

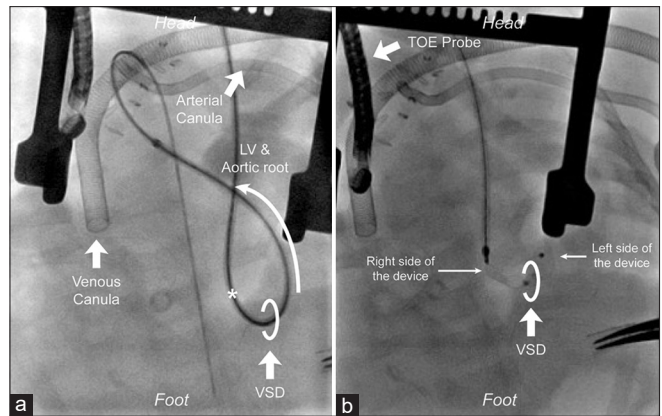


Figure 2: Fluoroscopic lateral view shows the perventricular access with delivery sheath and a guidewire combination passing through the apical defect into the left ventricular outflow tract and the aorta (a) and 8/6 Konar-MF™ device deployment (b). “*” represents the perventricular puncture site. LV: Left ventricle, VSD: Ventricular septal defect

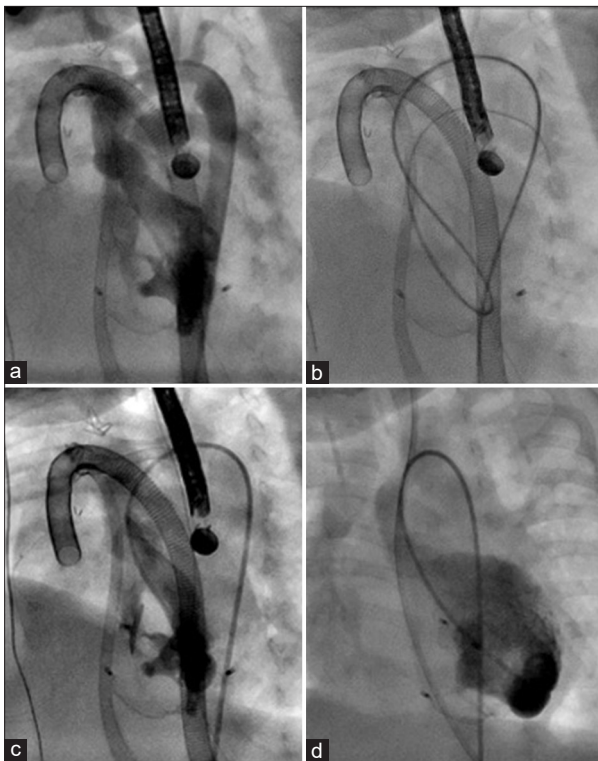


Figure 3: Fluoroscopic view. Left ventricular angiography showing a complex, left-to-right shunting, muscular ventricular septal defect (VSD) (a); VSD was crossed and a guidewire placed in the pulmonary artery (b); 7/5 Konar-MF™ device deployed (c); No residual VSD on final angiography after extracorporeal membrane oxygenation weaning (d)

we recognize the critical role of preoperative planning, and hybrid closure of the apical VSD may have been considered during the first surgery.

DISCUSSION

CE marked in 2018 and first used in North America in 2021

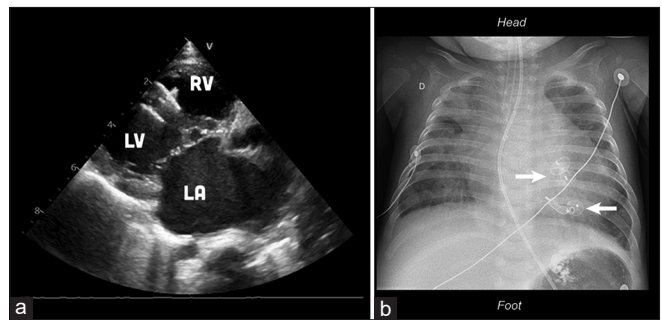


Figure 4: Two-year follow-up echocardiography (a) and thoracic chest X-ray (b) showing Konar-MF™ devices apposition with no residual shunt. LA: Left atrium, LV: Left ventricle, RV: Right ventricle

for transcatheter VSD closure on a compassionate basis,^[1] the MFO featured a high conformability with the defect to close. Due to its high conformability, self-expanding, and hybrid design incorporating both single- and double-disc concepts with articulated unilateral expansion, this MFO enables adaptability to various anatomies and procedural flexibility, which collectively facilitates its optimal use in achieving the desired outcome. Nevertheless, data regarding the safety and efficiency of perventricular device closure of complex muscular VSD are limited. Our case illustrates that both percutaneous and perventricular closure of surgically challenging VSD may be safely performed in a critically ill, low-body-weight infant using this soft, conformable device. The MFO enabled the successful closure of a surgically challenging apical and trabecular defect through a combined approach. A wide experience and extended follow-up after the use of MFO would place this device in the current armamentarium for VSD closure in low-body-weight infants.

Declaration of patient consent

The authors certify that they have obtained all

appropriate patient consent forms. In the form, the legal guardian has given his consent for images and other clinical information to be reported in the journal. The guardian understands that names and initials will not be published and due efforts will be made to conceal patient identity, but anonymity cannot be guaranteed.

Financial support and sponsorship

PP received financial support by the French Federation of Cardiology; A.-E.B is supported by the French Government as part of the “Investments of the future” program managed by the National Research Agency (grant

reference ANR-16-IDEX-0007). The funders have no role in the management of this case report.

Conflicts of interest

There are no conflicts of interest.

REFERENCE

1. Bjorkman KR, Aldoss O, Maldonado JR, McLennan D. Transcatheter utilisation of lifetech multifunction™ occluder device for closure of perimembranous and muscular ventricular septal defects: First use in North America. *Cardiol Young* 2021;31:1525-7.