



HAL
open science

Delayed diagnosis of urinary tuberculosis

Robin Dhersin, Paul Bazeries, Rachel Chenouard, Vincent Dubée

► **To cite this version:**

Robin Dhersin, Paul Bazeries, Rachel Chenouard, Vincent Dubée. Delayed diagnosis of urinary tuberculosis. CMAJ, 2022, 194 (8), pp.E310-E310. 10.1503/cmaj.210889 . hal-04758735

HAL Id: hal-04758735

<https://nantes-universite.hal.science/hal-04758735v1>

Submitted on 29 Oct 2024

HAL is a multi-disciplinary open access archive for the deposit and dissemination of scientific research documents, whether they are published or not. The documents may come from teaching and research institutions in France or abroad, or from public or private research centers.

L'archive ouverte pluridisciplinaire **HAL**, est destinée au dépôt et à la diffusion de documents scientifiques de niveau recherche, publiés ou non, émanant des établissements d'enseignement et de recherche français ou étrangers, des laboratoires publics ou privés.



Distributed under a Creative Commons Attribution - NonCommercial - NoDerivatives 4.0 International License

Delayed diagnosis of urinary tuberculosis

Robin Dhersin MD, Paul Bazeries MD, Rachel Chenouard MD, Vincent Dubée MD PhD

■ Cite as: *CMAJ* 2022 February 28;194:E310. doi: 10.1503/cmaj.210889

A 37-year-old man, who had immigrated from Romania 4 years prior, presented to the emergency department after several months of frequent urination and right-sided lumbar pain. Urine microscopy showed leukocytosis and hematuria. His urine bacterial culture was negative and renal function was normal. An abdominal computed tomography (CT) scan showed right kidney abscesses and thickening of the bladder and urethral walls (Figure 1A). He received a diagnosis of complicated upper urinary tract infection (UTI), and was treated with levofloxacin.

Six months later, the patient presented again with similar symptoms. Repeat urine culture was negative and he was empirically treated with trimethoprim-sulfamethoxazole. One year after initial presentation, the patient still had urinary tract symptoms. Upon receiving a CT scan for a dental abscess, he was found to have apical pulmonary micronodules with centrolobular distribution.

Given the low prevalence of UTIs in young men, and the patient's chronic sterile pyuria, failure to respond to antibiotics and pulmonary findings on CT, we suspected genito-urinary tract tuberculosis. He was referred to our infectious disease service. A repeat CT scan showed parenchymal cavitation. Urine testing with auramine staining, showed acid-fast bacilli, and urinary polymerase chain reaction (PCR) and culture were positive for *Mycobacterium tuberculosis*. We treated the patient with rifampin, isoniazid, pyrazinamide and ethambutol, but he developed partial destruction of renal tissue, ureteral stenosis and severe shrinkage of the bladder (Figure 1B). At 1-year follow-up, he had developed renal impairment, with an estimated glomerular filtration rate of 71 mL per minute.

Genitourinary tuberculosis is the third most common site of infection, accounting for 10% of cases.¹ The gold standard for diagnosis is mycobacterial culture from urine, but the organism can take weeks to grow; PCR may provide a quicker diagnosis, with a sensitivity of 89% and a specificity of 95%.² Prognosis of genitourinary lesions is

poor, as they often lead to persistent lower urinary tract symptoms and renal failure.^{1,3,4} Damage is often irreversible, but reconstructive surgery may mitigate persistent symptoms.¹

Clinicians should consider genitourinary tuberculosis in patients who present with sterile pyuria, have risk factors for tuberculosis and fail to respond to standard treatment for UTI.⁵

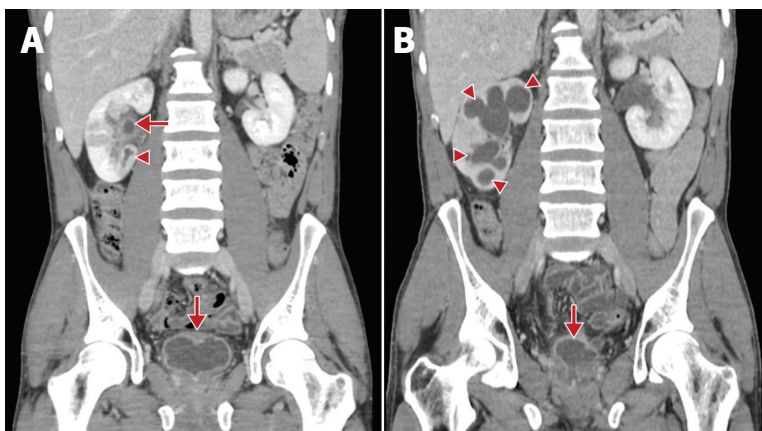


Figure 1: Computed tomography scans from a 37-year-old man with urinary tract tuberculosis. (A) Scan from first presentation, showing an abscess of the lower pole of the right kidney (arrowhead), and thickening of the renal pelvis and bladder walls (arrows). (B) Scan from 3 months after starting treatment for tuberculosis, showing progression of right hydronephrosis (arrowheads) and severe shrinkage of the bladder (i.e., thimble bladder) (arrow).

References

- Zajackowski T. Genitourinary tuberculosis: historical and basic science review: past and present. *Cent European J Urol* 2012;65:182-7.
- Chen K, Malik AA, Nantasamat C, et al. Clinical validation of urine-based Xpert® MTB/RIF assay for the diagnosis of urogenital tuberculosis: a systematic review and meta-analysis. *Int J Infect Dis* 2020;95:15-21.
- Krishnamoorthy S, Palaniyandi V, Kumaresan N, et al. Aspects of evolving genito urinary tuberculosis: a profile of genito urinary tuberculosis (GUTB) in 110 patients. *J Clin Diagn Res* 2017;11:PC01-05.
- Ramachandran A, Das CJ, Razik A. Male genital tract tuberculosis: a comprehensive review of imaging findings and differential diagnosis. *Abdom Radiol (NY)* 2021;46:1677-86.
- Wise GJ, Schlegel PN. Sterile pyuria. *N Engl J Med* 2015;372:1048-54.

Competing interests: None declared.

This article has been peer reviewed.

The authors have obtained patient consent.

Affiliations: Departments of Infectious Diseases (Dhersin, Dubée), Department of Radiology (Bazeries) and Microbiology (Chenouard), Angers University Hospital, Angers, France; CRCINA (Dubée), Inserm, Université de Nantes, Nantes, France

Content licence: This is an Open Access article distributed in accordance with the terms of the Creative Commons Attribution (CC BY-NC-ND 4.0) licence, which permits use, distribution and reproduction in any medium, provided that the original publication is properly cited, the use is noncommercial (i.e., research or educational use), and no modifications or adaptations are made. See: <https://creativecommons.org/licenses/by-nc-nd/4.0/>

Acknowledgement: The authors thank Jessica Peltzer (Department of Anesthesiology, Caen University Hospital, France) for her review of this manuscript's grammar and syntax.

Correspondence to: Vincent Dubée, vdubee@gmail.com