



**HAL**  
open science

## **Immune-related adverse events with bispecific T-cell engager therapy targeting B-cell maturation antigen.**

Bénédicte Piron, Mathilde Bastien, Chloé Antier, Romain Dalla-Torre, Bastien Jamet, Thomas Gastinne, Viviane Dubruille, Philippe Moreau, Jérôme Martin, Antoine Bénichou, et al.

### ► To cite this version:

Bénédicte Piron, Mathilde Bastien, Chloé Antier, Romain Dalla-Torre, Bastien Jamet, et al.. Immune-related adverse events with bispecific T-cell engager therapy targeting B-cell maturation antigen.. *Haematologica*, 2023, 109 (1), pp.357-361. 10.3324/haematol.2023.282919 . hal-04753539

**HAL Id: hal-04753539**

**<https://nantes-universite.hal.science/hal-04753539v1>**

Submitted on 25 Oct 2024

**HAL** is a multi-disciplinary open access archive for the deposit and dissemination of scientific research documents, whether they are published or not. The documents may come from teaching and research institutions in France or abroad, or from public or private research centers.

L'archive ouverte pluridisciplinaire **HAL**, est destinée au dépôt et à la diffusion de documents scientifiques de niveau recherche, publiés ou non, émanant des établissements d'enseignement et de recherche français ou étrangers, des laboratoires publics ou privés.



Distributed under a Creative Commons Attribution 4.0 International License

# Immune-related adverse events with bispecific T-cell engager therapy targeting B-cell maturation antigen

Bispecific antibodies (BispAb) targeting BCMAxCD3 have been recently approved for the treatment of patients with relapsed and refractory myeloma previously exposed to immunomodulatory drug, proteasome inhibitor, and anti-CD38 antibodies. For instance, the phase I/II MajesTEC-1 study demonstrated high efficacy of teclistamab in advanced (median of 5 prior lines), triple-class exposed and refractory myeloma, with an overall response rate of 63% and median progression-free survival of 11.3 months.<sup>1</sup> In BispAb studies, most common treatment-emergent adverse events (AE) were cytokine release syndrome (CRS), hematological toxicities and immune effector cell associated neurotoxicity syndrome. Dysimmune events were neither observed nor classified as such but were exclusion criteria for protocol enrollment.<sup>2</sup> Immune-related adverse events (irAE) are well described for the immune checkpoint inhibitor therapy such as anti-PD1 or anti-CTLA-4. This type of AE could affect different organs, such as gastrointestinal, endocrinological, skin or rheumatological systems.<sup>3</sup> The explanation of these irAE under checkpoints inhibitors seems straightforward with the activity enhancement of T cells.<sup>3</sup> Thus, through two thoroughly documented clinical cases, we report here how dysimmunity could be induced by T-cell engaging BispAb, with very different patterns of symptoms.

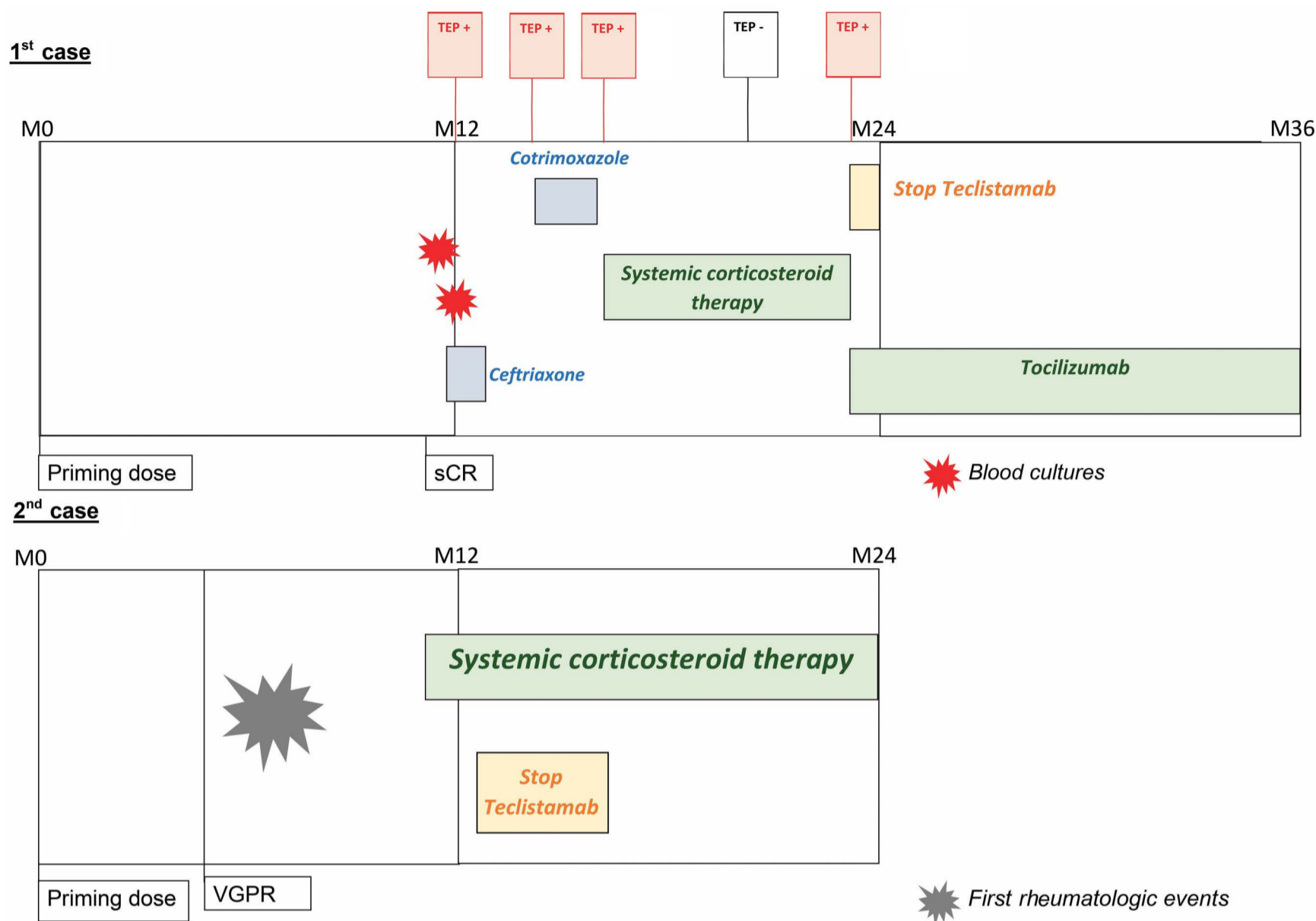
## Case 1

Case 1 is a 77-year-old woman without a significant medical history, who has been treated for IgG  $\kappa$  multiple myeloma. Her ninth line consisted of a CD3xBCMA BispAb, a stringent complete remission (sCR) from the 13<sup>th</sup> cycle was obtained. A grade 1 CRS was noted at first cycle and was resolutive. Shortly after sCR, the patient presented with recurring oligoarthritis. There was a biological inflammatory syndrome (C reactive protein [CRP] increased and thrombocytosis). Blood cultures were positive twice for *Neisseria cinerea*, and while echocardiography showed no signs of infective endocarditis, she was treated with ceftriaxone (2 g/day) for 14 days and the oligoarthritis was resolved (Figure 1). The positron emission tomography-computed tomography (PET-CT) scan that had been performed for the disease's extension showed grade 3 (the highest grade) parietal hypermetabolism of the thoracic aorta, brachiocephalic artery trunk, right subclavian artery, and left common iliac artery (Figure 2A-D, bottom row with arrows). On examination, no recent or previous cephalic, visual, mandibular, or rhizome manifestations, no chest, back, abdominal, or lumbar pain with an inflam-

matory appearance were observed. The temporal and peripheral pulses were perceived without vascular murmur. Except moderate inflammatory syndrome with a CRP of 8 mg/L, blood results were normal. Blood cultures and infectious serologies were negative. Systematic etiological exams for inflammatory vasculitis were negative. The temporal artery biopsy didn't demonstrate Horton's disease. Ultrasound-Doppler of the encephalic and temporal arteries demonstrated a significant diffuse hyperplasia of the *intima*, at the origin of the right subclavian artery. A segmental inflammatory aspect of the trunk of the left temporal artery with halo sign was also noticed (UltraSound findings, data not shown). Given the context of severe immunosuppression and recent infection, this arthritis was presumed to be related to an infectious cause, relying on ceftriaxone treatment to recover. No improvement of PET-CT findings at 8 weeks from arthritis diagnosis were noted. It was decided to start a second line therapy with cotrimoxazole for 8 weeks. The patient underwent a new PET-CT after 2 months, with no improvement (vasuclar PET scan [PETVasc] global 27/48). A PETVasc is an additional score with a maximum score at 48 (Figure 2A, C, top and bottom rows). A systemic corticosteroid therapy at a dose of 0.7 mg/kg/day in progressive decrease over 12 months was introduced (Figure 1). Several PET-CT showed a clear decrease in segmental hyperfixation of the wall of large and medium-sized vessels (PETVasc global 23/48) (Figure 2A, C, D). End-of-treatment PET-CT, performed just after steroid withdrawal, showed an iconographic relapse. Referring to the teclistamab-induced vasculitis, internists introduced tocilizumab subcutaneous weekly, with maintaining corticotherapy. teclistamab was stopped during the first month (Figure 1).

## Case 2

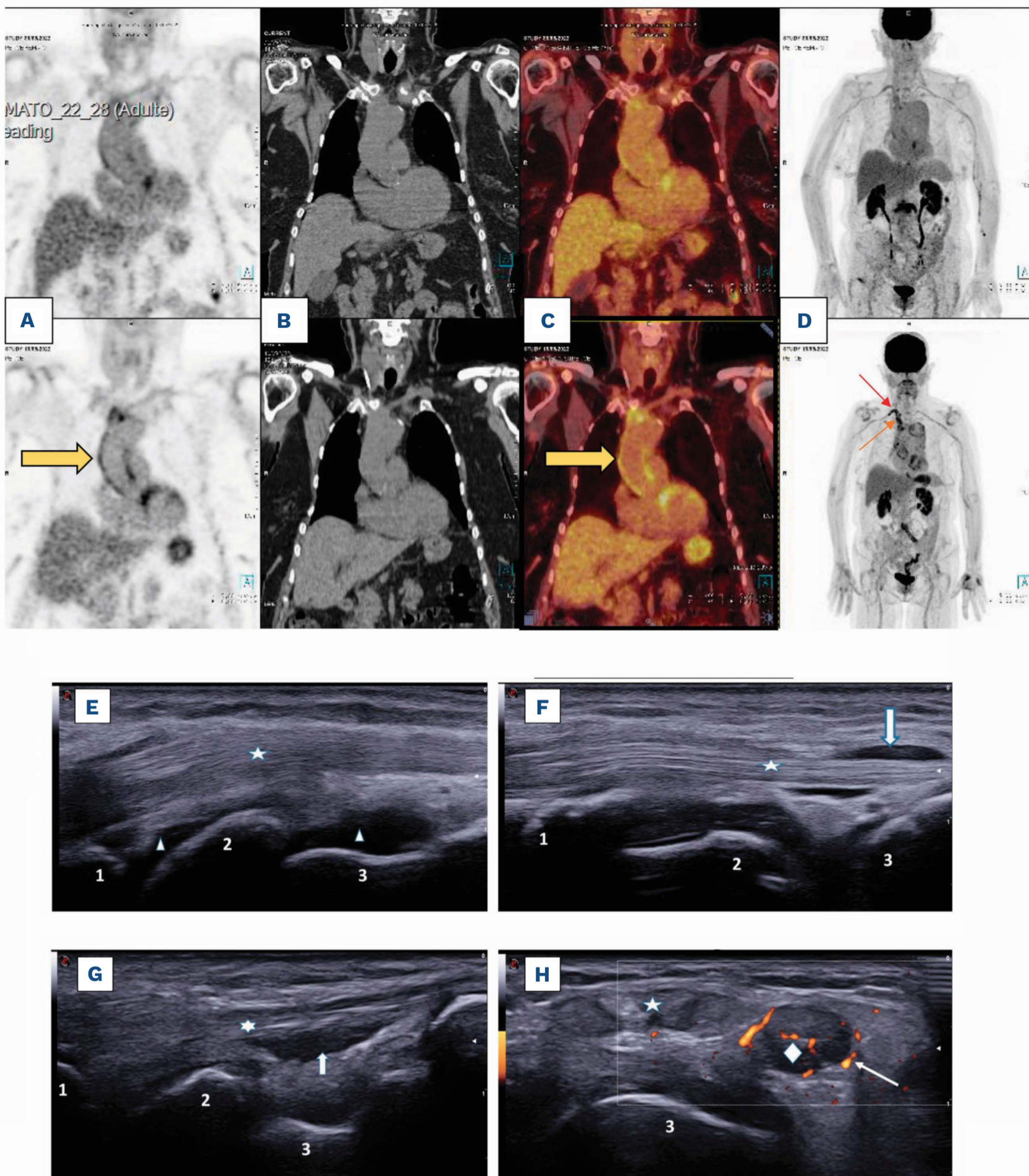
The second case reported here concerns a 66-year-old woman with a notable history of immune thrombocytopenia (ITP) refractory to corticosteroid (splenectomy in 1995). She was diagnosed with a symptomatic multiple myeloma, treated with five lines. After the first cycle of CD3xBCMA BispAb, a grade 1 CRS with ITP decompensation (resolved with intravenous immunoglobulin) was observed. At the beginning of cycle 11, the patient presented with an abrupt polyarticular presentation with distal interphalangeal joint and proximal interphalangeal joint (PIJ) swelling of the third and second fingers of the left hand, as well as the carpometacarpal joint of the second finger of the left hand. Pain of the left knee and hip, with morning rusting were also



**Figure 1. Clinical, radiological, and therapeutical chronology of the two cases.** M: month; sCR: stringent complete remission; VGPR: very good partial response; TEP: tomography by emission of positrons.

notified. At the beginning of the 12<sup>th</sup> cycle, the inflammatory rhythm polyarthralgias were still present, but migratory also with swelling of the ankles. No family history of inflammatory rheumatism, no uveitis, no dactylitis, no transit abnormalities were reported. Blood testing was normal for uric acid. The immune checkup came back as negative (antinuclear antibodies, rheumatoid factors and anti-CCP) as well as infectious investigations (blood culture, hepatitis polymearse chain reaction). On X-rays, there were some erosions suspected as consequences of inflammation without argument for chondrocalcinosis or osteoarthritis. Ultrasound-Doppler images (Figure 2E-H), there was a grade 2 synovitis of wrists and PIJ. Furthermore, there was a tenosynovitis of the common extensors of the fingers and there were bilateral crural synovitis and fibular tenosynovitis of the ankles. The patient has been recovering gradually under corticosteroid therapy introduced as 10 mg per day with a continuous tapering. From the first dose decrement, complete regression of the morning rusting in the lower limbs was observed, followed by disappearance of hands and wrist synovitis symptoms. Teclistamab was discontinued 3 months (Figure 1).

These two cases illustrate two presumed irAE due to BispAb during multiple myeloma treatment. Indeed, in the first case, it seems particularly challenging to decipher whether it is primary inflammatory vasculitis or potentially induced by BispAb. However, the germ involved here, which usually damages the small vessel walls directly, has been controlled by prolonged antibiotic therapy and is, therefore, unlikely to be the cause of persistent vasculitis.<sup>4</sup> Relating those events to drug exposure may be contra-intuitive as most AE related to BispAb are on the side of immunosuppression. Indeed, it may seem paradoxical that an antibody targeting BCMA can induce autoimmune reactions while some drugs targeting its soluble receptor/ligand (BAFF) is used to treat autoimmune disease with belimumab for instance,<sup>5</sup> this situation has been extensively described for anti-TNF $\alpha$  therapy in *genesis lupus*.<sup>6</sup> Biological rationale may enlighten this particular course of events. Important to remember is that BCMA is a transmembrane receptor naturally expressed on plasma cells and is consistently expressed at high levels on malignant plasma cells. BCMA binds to BAFF, a cytokine expressed by B-lineage cells, and leads to the activa-



**Figure 2. Positron emission tomography and ultrasound pictures of the two cases.** (A-D) Positron emission tomography (PET)-computed tomography (CT) scans showing grade 3 parietal hypermetabolism of the thoracic aorta, brachiocephalic artery trunk, right subclavian artery, and left common iliac artery. Case 1 : (A) PET coronals, (B) CT coronals, (C) fused coronals, (D) whole body PET. Top row: after corticotherapy; bottom row: before corticotherapy. Red arrow: right subclavian artery hypermetabolism; orange arrow: right brachiocephalic trunk hypermetabolism. Case 2 (E-H): (E) right radiocarpal synovitis, longitudinal section (B mode), (F) right tenosynovitis, extensor digitorum communis (B mode), (G) right tenosynovitis, flexor digitorum communis (B mode), (H): right tenosynovitis, extensor digitorum brevis and extensor digitorum longus with Doppler hyperemia. Triangle stands for radial and medial carpal synovitis (E only). Numbers 1, 2, and 3, respectively stand for radius, lunatum, and capitatum; five- and six-pointed stars respectively stand for extensor digitorum communis, and flexor digitorum communis (G). Diamond in (H) stands for the extensor digitorum brevis and the extensor digitorum longus. Large arrow in (F, G) highlights synovitis effusion around tendon sheaths. Thin arrow in (H) demonstrates doppler vascularization.

**Table 1.** Effects of the lack of BAFF or BCMA in murine lupus model.

Deficiency	Mouse strain	Result
BAFF	NZM2328	Delay in autoantibodies
BCMA	Nba2.Yaa	Enhances autoantibodies and exacerbates disease
	NZM2328	Increased spleen size No effect on autoantibodies, plasma cells or mortality

Table adapted with permission from Jackson and Davidson. Immunol Rev. 2019.<sup>9</sup>

tion of kinases (MAPK8/JNK) by NFκB transcription that stimulate plasma cells to maintain humoral immunity. BAFF is required for normal B-cell homeostasis, but it also promotes the survival of malignant B cells. BCMA can also bind to a related protein, APRIL involved in B-cell development and autoimmune response. The complex interactions between BCMA and its ligands BAFF and APRIL explain BCMA implication in the maintenance of plasma cells, but also in several cancers, autoimmune and infectious diseases.<sup>7</sup> This effect could be explained by the increase of the BCMA's ligand levels along with the inhibition of its receptor *via* bispecific therapies in multiple myeloma (CD3-BCMA). BCMA may give rise to dysimmune disease *via* its targeting. Supporting this hypothesis, BCMA deficiency in mice exacerbated phenotypes with dysimmune diseases<sup>8</sup> (Table 1). Different studies have shown that serum levels of BAFF were associated with a major disease activity.<sup>10</sup> When BCMA is allosterically occupied, other BCMA ligands could increase, and would likely bind to its targets (BAFF-R and APRIL-R) (Table 1). Indeed, this explains why some immunotherapy treatments for autoimmune diseases (such as lupus or vasculitis<sup>11</sup>), take leverage of this effect, such as atacicept<sup>12</sup> which targets both BAFF and APRIL-R; or tabalumab<sup>13</sup> which also targets both BAFF and BCMA. The second hypothesis for the development of post-BCMA autoimmunity could be explained by the expansion of follicular T-helper cells. Indeed, the uncontrolled expansion of follicular T-helper cells (TFH) activates autoreactive B cells to produce antibodies inducing autoimmunity. TFH cells express BCMA and BR3 receptors and accumulate in the spleen when BCMA is absent. BCMA deficiency in T cells can promote TFH cell expansion, autoantibody production, and IFNγ production by TFH cells *via* BR3.<sup>3</sup> In an experimental study,<sup>14</sup> blocking BAFF or IFNγ *in vivo* reduced TFH cell accumulation and improved autoimmunity in BCMA-deficient animals but not in BR3-deficient ones. BCMA acts intrinsically to T cells to limit the number of autoreactive TFH, and thereby regulates autoreactive B-cell responses.<sup>15</sup> BAFF blocking agents could be evaluated to reduce autoimmune reactions related to BCMAxC3 BispAb. However, we cannot neglect that there were no strong reports of dysimmunity with other anti-BCMA therapies as

cytotoxic coupled-agents (e.g., belantamab mafodotin) or chimeric antigen receptor T cells (e.g., Ide-cel or Cilta-cel). Thus, we can hypothesize that bispecific agents with T-cell engagement may increase unspecific T-cell response or reverse T-cell exhaustion,<sup>16</sup> leading to dysimmunity. Against this assumption, dysimmune events with using other BispAb (targeting GPRC5D or FcRH5) were not reported. Thus, incidence and physiopathology of these dysimmune complications need to be explored in prospective studies with more patients and longer follow-up.

## Authors

Bénédicte Piron,<sup>1</sup> Mathilde Bastien,<sup>1</sup> Chloé Antier,<sup>1</sup> Romain Dalla-Torre,<sup>2</sup> Bastien Jamet,<sup>3</sup> Thomas Gastinne,<sup>1</sup> Viviane Dubruille,<sup>1</sup> Philippe Moreau,<sup>1,4,5</sup> Jérôme Martin,<sup>6</sup> Antoine Bénichou,<sup>7</sup> Cyrille Touzeau<sup>1,4,5</sup> and Benoît Tessoulin<sup>1,4</sup>

<sup>1</sup>Department of Hematology, University Hospital; <sup>2</sup>Department of Rheumatology, University Hospital; <sup>3</sup>Department of Nuclear Medicine, University Hospital; <sup>4</sup>Centre de Recherche en Cancérologie et Immunologie Intégrée Nantes Angers, INSERM UMR 1307, CNRS UMR 6075; <sup>5</sup>Site de Recherche Intégrée sur le Cancer (SIRIC), Imaging and Longitudinal Investigations to Ameliorate Decision-Making (ILIAD), INCA-DGOS-INSERM 12558, Immunology Laboratory, CIMNA; <sup>6</sup>Immunology Laboratory, CIMNA and <sup>7</sup>Department of Internal and Vascular Medicine, University Hospital, Nantes, France

Correspondence:

B. TESSOULIN - benoit.tessoulin@chu-nantes.fr

<https://doi.org/10.3324/haematol.2023.282919>

Received: March 15, 2023.

Accepted: July 11, 2023.

Early view: July 20, 2023.

©2024 Ferrata Storti Foundation

Published under a CC BY-NC license 

### Disclosures

No conflicts of interest to disclose.

### Contributions

BP, CT and BT wrote the manuscript. BP, MB, CA, TG, VD, CT, RDT, AB and BT treated the patients. RDT and BJ provided imaging data. All authors critically reviewed the manuscript.

### Data-sharing statement

Data supporting this article are available from the corresponding author.

## References

---

1. Moreau P, Girgis S, Goldberg JD. Teclistamab in relapsed or refractory multiple myeloma. Reply. *N Engl J Med*. 2022;387(18):1722-1723.
2. Usmani SZ, Garfall AL, van de Donk NWCJ, et al. Teclistamab, a B-cell maturation antigen × CD3 bispecific antibody, in patients with relapsed or refractory multiple myeloma (MajesTEC-1): a multicentre, open-label, single-arm, phase 1 study. *Lancet*. 2021;398(10301):665-674.
3. Sophia C, Weinmann and David S. Pisetsky. Mechanisms of immune-related adverse events during the treatment of cancer with immune checkpoint inhibitors. *Rheumatology (Oxford)*. 2019;58(Suppl 7):vii59-vii67.
4. Teng GG, Chatham WW. Vasculitis related to viral and other microbial agents. *Best Pract Res Clin Rheumatol*. 2015;29(2):226-243.
5. Jin X, Ding C. Belimumab—an anti-BLyS human monoclonal antibody for rheumatoid arthritis. *Expert Opin Biol Ther*. 2013;13(2):315-322.
6. De Bandt M. Anti-TNF-alpha-induced lupus. *Arthritis Res Ther*. 2019;21(1):235.
7. Khattar P, Pichardo J, Jungbluth A, et al. B-cell maturation antigen is exclusively expressed in a wide range of B-cell and plasma cell neoplasm and in a potential therapeutic target for Bcma directed therapies. *Blood*. 2017;130(Suppl 1):S2755.
8. Jacob CO, Yu N, Sindhava V, et al. Differential development of systemic lupus erythematosus in NZM 2328 mice deficient in discrete pairs of BAFF receptors. *Arthritis Rheumatol*. 2015;67(9):2523-2535.
9. Jackson SW, Davidson A. BAFF inhibition in SLE-Is tolerance restored? *Immunol Rev*. 2019;292(1):102-119.
10. Fang Wei, Yan Chang, Wei Wei. The role of BAFF in the progression of rheumatoid arthritis. *Cytokine*. 2015;76(2):537-544.
11. Alesaeidi S, Darvishi M, Dabiri S, et al. Current understanding and unknown aspects of the treatment of granulomatosis with polyangiitis (Wegener's granulomatosis): opportunities for future studies. *Curr Rheumatol Rev*. 2020;16(4):257-266.
12. Merrill JT, Wallace DJ, Wax S, et al. Efficacy and safety of ataccept in patients with systemic lupus erythematosus: results of a twenty-four-week, multicenter, randomized, double-blind, placebo-controlled, parallel-arm, phase IIb study. *Arthritis Rheumatol*. 2018;70(2):266-276.
13. Shaker OG, Tawfic SO, El-Tawdy AM et al. Expression of TNF- $\alpha$ , APRIL and BCMA in Behcet's disease. *J Immunol Res*. 2014;2014:380405.
14. Coquery CM, Loo WM, Wade NS, et al. BAFF regulates follicular helper t cells and affects their accumulation and interferon- $\gamma$  production in autoimmunity. *Arthritis Rheumatol*. 2015;67(3):773-784.
15. Jiang C, Loo WM, Greenley EJ, et al. B cell maturation antigen deficiency exacerbates lymphoproliferation and autoimmunity in murine lupus. *J Immunol*. 2011;186(11):6136-6147.
16. Gao Z, Feng Y, Xu J, Liang J. T-cell exhaustion in immune-mediated inflammatory diseases: new implications for immunotherapy. *Front Immunol*. 2022;13:977394.