



**HAL**  
open science

## Reconstruction techniques of the orbit after Brown class III maxillectomy : A systematic review

Sophie Dugast, Julie Longis, Marine Anquetil, Benoit Piot, Pierre Corre,  
Jean-françois Huon, Hélios Bertin

### ► To cite this version:

Sophie Dugast, Julie Longis, Marine Anquetil, Benoit Piot, Pierre Corre, et al.. Reconstruction techniques of the orbit after Brown class III maxillectomy : A systematic review. *Head & Neck*, 2023, 45 (6), pp.1581 - 1593. 10.1002/hed.27352 . hal-04304570

**HAL Id: hal-04304570**


**<https://nantes-universite.hal.science/hal-04304570>**

Submitted on 24 Nov 2023

**HAL** is a multi-disciplinary open access archive for the deposit and dissemination of scientific research documents, whether they are published or not. The documents may come from teaching and research institutions in France or abroad, or from public or private research centers.

L'archive ouverte pluridisciplinaire **HAL**, est destinée au dépôt et à la diffusion de documents scientifiques de niveau recherche, publiés ou non, émanant des établissements d'enseignement et de recherche français ou étrangers, des laboratoires publics ou privés.

# Reconstruction techniques of the orbit after Brown class III maxillectomy: A systematic review

Sophie Dugast MD<sup>1</sup> | Julie Longis MD<sup>1</sup> | Marine Anquetil MD<sup>1</sup> |  
 Benoît Piot MD<sup>1</sup> | Pierre Corre MD, PhD<sup>1,2</sup> |  
 Jean-François Huon PharmD, PhD<sup>3,4</sup> | Hélios Bertin MD, PhD<sup>1,5</sup> 

<sup>1</sup>University of Nantes, CHU Nantes, Service de Chirurgie Maxillo-Faciale et Stomatologie, F-44000 Nantes, France

<sup>2</sup>University of Nantes, Oniris, Univ Angers, CHU Nantes, INSERM, Regenerative Medicine and Skeleton, RMeS, UMR 1229, F-44000 Nantes, France

<sup>3</sup>University of Nantes, CHU Nantes, Pharmacie, F-44000 Nantes, France

<sup>4</sup>University of Nantes, Univ Tours, CHU Nantes, CHU Tours, INSERM, MethodS in Patients-centered outcomes and HEalth Research, SPHERE, F-44000 Nantes, France

<sup>5</sup>University of Nantes, Univ Angers, CHU Nantes, INSERM, CNRS, CRCI2NA, F-44000 Nantes, France

## Correspondence

Hélios Bertin, University of Nantes, CHU Nantes, Service de Chirurgie Maxillo-Faciale et Stomatologie, F-44000 Nantes, France.

Email: [helios.bertin@chu-nantes.fr](mailto:helios.bertin@chu-nantes.fr)

## Funding information

Fondation les Gueules Cassées,  
 Grant/Award Number: 2018-51

## Abstract

This systematic review aimed to evaluate the surgical techniques used for orbital floor reconstruction after Brown class III maxillectomy for cancer. Three databases were searched from January 1990 to January 2022. Of the 614 studies identified, 20 were retained after eligibility assessment. The surgical techniques were classified into four groups: free bone flaps (A), alloplastic implants (B), bone grafts (C), and soft-tissue reconstructions (D). Ectropion and diplopia concerned 42.6% and 6.6% of the patients, respectively. Soft tissue reconstruction was more likely to cause ectropion (17/27), followed by the reconstruction techniques of group B (34/79), group C (26/70), and group A (1/7). Postoperative enophthalmos was identified in 18 patients (9.6%), mostly in group D (5/35), followed by groups B (8/68), A (3/33), and C (2/52). Free bone flaps and alloplastic implants represent good reconstructive options in terms of postoperative ocular parameters.

## KEYWORDS

cancer, maxillary, orbit surgery, reconstruction, systematic review

## 1 | INTRODUCTION

Maxillary tumors are rare malignancies representing 3%–5% of all head and neck cancers, with the main histology being squamous cell carcinoma (SCC).<sup>1,2</sup> The recommended treatment is based on complete surgical removal

of the lesion involving all or part of the maxillary bone and sometimes reaching the orbital bone structures, with adjuvant radiotherapy.<sup>3</sup> For several years, improvements in reconstruction techniques have enabled more extensive resections, thereby allowing better local control of these tumors. Reconstruction of total maxillectomies

This is an open access article under the terms of the [Creative Commons Attribution](https://creativecommons.org/licenses/by/4.0/) License, which permits use, distribution and reproduction in any medium, provided the original work is properly cited.

© 2023 The Authors. *Head & Neck* published by Wiley Periodicals LLC.

remains one of the most delicate procedures in the head and neck region.<sup>4</sup>

Primary reconstruction, that is, during the carcinologic excision procedure, should be undertaken as often as possible.<sup>5</sup> As with all oncological reconstructions, the main objectives are to ensure survival of the patient, to restore the orofacial functions (breathing, vision, chewing, and speech) and, as much as possible, to provide a socially acceptable aesthetic result. Several algorithms for the management of different types of maxillectomies have been proposed.<sup>6,7</sup> The Brown classification of maxillary defects is widely used, as it refers to both the vertical and horizontal components of the maxillectomy, thereby allowing three-dimensional (3D) visualization of the area to be reconstructed.<sup>4,8</sup> Brown class III maxillectomy refers to the total removal of the maxillary bone and the lower part of the orbit, thus requiring an appropriate reconstruction of the orbital floor. Owing to the rarity of maxillary tumors, there is currently no consensus regarding the orbit reconstruction of Brown class III maxillary defects. The reconstruction aims to provide support to the orbital contents to maintain its function and satisfactory facial symmetry. These reconstructions are even more challenging as they are often the site of additional radiotherapy, which increases the risk of specific functional and aesthetic sequelae (e.g., diplopia, ectropion, enophthalmos, and lagophthalmos).<sup>9</sup> Various surgical techniques have been described to ensure support of the orbital contents after removal of the orbital floor. Free bone flap procedures using a fibula flap, an iliac crest flap, and even a costal free flap are currently used because of their reliability and their lower bone resorption compared with bone grafts.<sup>10–14</sup> Free bone flaps allow both restoration of the maxillary arch for dental rehabilitation as well as orbit reconstruction by providing a solid and stable bone support for the orbital content.<sup>12,15,16</sup> The use of autologous bone grafts including rib, calvaria, or iliac crest grafts covered by free or pedicled soft tissue flaps have also been described.<sup>7,12,17–21</sup> These techniques are often considered at risk of exposure, infection, and bone resorption, especially after radiotherapy. The use of alloplastic implants such as titanium mesh has also been reported. Despite promising aesthetic and functional results, the risk of material exposure and infection is significant in light of the frequent use of post-operative irradiation.<sup>22–28</sup> Finally, some authors favor reconstruction of the orbital floor with soft tissues and in particular with fascia lata strips because of their ease, the rapidity of harvesting, as well as their lower risk of complications.<sup>29–31</sup>

By means of a systematic review of the literature, the objective of this study was to compare the different surgical techniques used for reconstruction of the orbital floor

after Brown class III maxillectomies for malignant tumors in terms of functional and aesthetic parameters.

## 2 | MATERIALS AND METHODS

This systematic review was conducted in accordance with the items of the PRISMA-NMA (Preferred Reporting Items for Systematic Reviews and Meta-Analyses—Network Meta-Analyses) checklist,<sup>32</sup> and registered on PROSPERO (CRD42021269910).

### 2.1 | Search strategy

A systematic search was carried out of three different literature databases: PubMed, Cochrane Library, and Google Scholar. The following terms were used for this: ((maxillectomy[Title/Abstract]) OR (maxillary resection [Title/Abstract]) OR (maxilla resection[Title/Abstract]) OR (upper jaw resection[Title/Abstract]) OR (midfacial resection[Title/Abstract]) OR (midface resection[Title/Abstract])) AND (orbit\*[Title/Abstract]). The search was restricted to articles published between January 1990 and January 2022. A first reading allowed selection of the relevant titles, a second reading the abstracts, and a final reading the articles that could be included. The eligibility criteria were assessed separately by two reviewers (S.D. and H.B.) at each stage of the study. In case of disagreement, a third reviewer (J.F.H.) made the final decision.

Inclusion criteria:

- Primary reconstruction of Brown class III maxillary defects
- Malignant tumors of the maxilla
- A minimum of five patients studied
- Assessment of functional, aesthetic, and survival results.

Exclusion criteria:

- Secondary reconstruction
- Brown class III maxillectomy without orbit reconstruction
- Benign tumors or post-traumatic defects
- Lack of clinical evaluation.

### 2.2 | Data collection

Data was extracted using a structured data collection form and included the following information: Type of

study design, number of patients analyzed in each study, demographic data (age and gender), histopathology, the need for adjuvant radiotherapy, and follow-up time. The main evaluation criteria were the visual functional parameters after orbital reconstruction, including diplopia, the presence of postoperative ectropion, and decreased visual acuity (DVA). The secondary endpoints included aesthetic parameters (enophthalmos, malposition of the globe, and facial asymmetry), and potential postoperative complications in accordance with the reconstruction technique.

To provide a framework for interpretation of the results, we classified the reconstruction techniques into four different groups:

- *Group A* included reconstruction of the orbital framework by use of a free bone flap.
- *Group B* combined the alloplastic implants including titanium mesh, 3D implants, and absorbable sheets.
- *Group C* was represented by the techniques involving non-vascularized bone grafts.
- *Group D* included reconstruction techniques that used only soft tissue, most often a fascia lata strip associated with a free or pedicled non-bone flap.

### 2.3 | Risk of bias assessment

The level of evidence was evaluated using the Oxford Centre for Evidence-Based Medicine (OCEBM) criteria.<sup>33</sup> The risk of bias was evaluated using the Methodological Quality Assessment Tool (MQAT) for case reports and case series.<sup>34</sup> Each published article was assessed based on five aspects (patient selection, ascertainment, outcome, follow-up, and reporting). Two reviewing authors independently performed this critical appraisal of the included articles and scored the overall methodological quality (low, moderate, or high), based on the questions deemed most critical in the specific clinical scenario. The quality assessment outcomes of these studies are listed in Table A1.

## 3 | RESULTS

### 3.1 | Selection of the studies

Initial identification retrieved 614 articles, 44 articles progressed to full-text review, and 20 studies were selected according to the inclusion and exclusion criteria (Figure 1). Of the 20 included studies all were retrospective, one was comparative<sup>31</sup> while the others were

descriptive. Three articles described the use of two different reconstruction techniques.<sup>12,21,29</sup>

### 3.2 | Patients' characteristics and surgical procedures

A total of 232 patients were enrolled, with a mean age ranging from  $40.0 \pm 7.11$  years<sup>21</sup> to  $59.4 \pm 12.6$  years,<sup>29</sup> depending on the study. The main histological diagnosis for maxillary tumors was SCC ( $n = 119$ ), followed by cystic adenoid carcinoma ( $n = 39$ ), sarcoma ( $n = 31$ ), and adenocarcinoma ( $n = 10$ ). Adjuvant radiotherapy concerned 26 patients of group A out of 27 patients for whom this data was analyzed, 55/85 patients of group B, 43/57 patients of group C, and 30/35 patients of group D. Preoperative radiotherapy involved 16 and 9 patients of groups B and C, respectively.

Various free bone flaps were included in group A. The tensor fascia lata (TFL)–iliac crest (IC) flap was mostly reported in light of the suitable shape of IC for orbital reconstruction, while the TFL was used to fill the palatal defect.<sup>13,31</sup> Kraft et al. described the use of a free serratus-rib flap where the rib recreated the orbital floor and the muscle component filled the maxillary defect.<sup>35</sup> Others flaps included fibula free flap (FFF), bony radial artery forearm (bony-RF) free flap, and free latissimus dorsi (LD) with rib.<sup>31</sup>

The reconstruction techniques with alloplastic implants (group B) largely relied on titanium-based materials. These implants consisted of a custom-made mesh manufactured based on the preoperative CT scan images, 3D implants, and mesh shaped intraoperatively. Patients reconstructed with absorbable sheets (polyethylene, L-lactide polyglycolide and trimethylene carbonate, beta-tricalcium phosphate, or poly-L-lactide polymer) were also included in this group. Custom-made 3D implants allowed the repair of the orbital floor, the lower orbital rim, the malar prominence, and the anterior maxillary wall up to the alveolus.<sup>22,23,28</sup> The implant could be combined with soft tissue or bone free flaps for reconstruction of the maxillary defect: anterior lateral thigh (ALT) flap,<sup>22,27,28</sup> FFF,<sup>15,16,27,28</sup> rectus abdominis (RA) muscle flap,<sup>28</sup> scapulo-dorsal (SD) flap,<sup>23</sup> LD,<sup>22,23</sup> TFL,<sup>36</sup> IC free flap,<sup>12</sup> or RF.<sup>26</sup> Some authors reported the use of a layered-FFF, consisting in three to five osteotomies to reconstruct the entire maxillary structure from the infraorbital rim to the alveolar ridge with a single flap, while the orbital floor was repaired with a titanium plate.<sup>15,16,27</sup> The use of a fascia temporalis (FT) pedicled flap was also reported.<sup>21,23</sup> Jung et al. did not report any flap support for orbit reconstruction, while the maxillary mucosal defect was covered with a harvested split-thickness skin graft.<sup>29</sup>

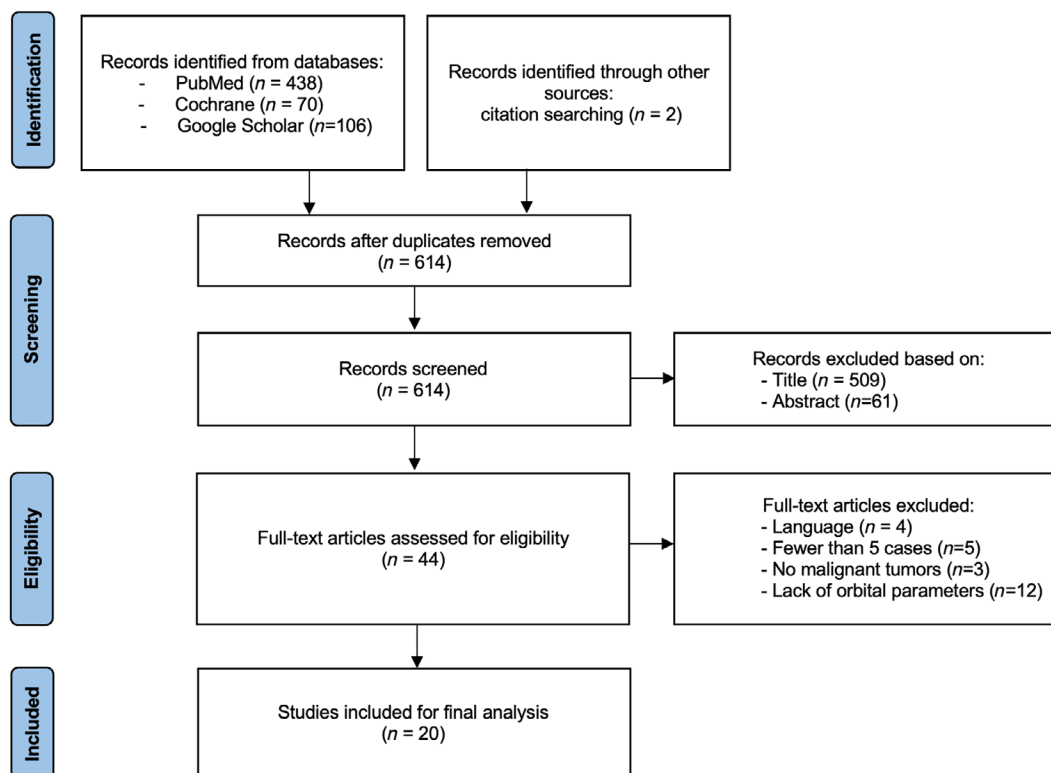


FIGURE 1 Flowchart of the selection process of the articles. [Color figure can be viewed at [wileyonlinelibrary.com](http://wileyonlinelibrary.com)]

The bone donor sites in group C included ribs, calvaria, iliac crest, and mandibular bones.<sup>7,12,17–21</sup> The graft was often fragmented to reshape the orbital floor and orbital walls. A soft tissue or bone flap was associated, either by a RA free flap,<sup>7,18–20</sup> or by a pedicled temporalis muscle (TM) flap<sup>17,19</sup> or an FT.<sup>21</sup>

Patients of group D received a FL sling fixed with non-absorbable sutures and titanium screws to the nasal bone, the lateral canthal tendon, and the remnant of the posterior orbital floor. The FL was used on its own in the study by Jung et al.,<sup>29</sup> whereas others authors associated the FL sling with a free soft-tissue flap.<sup>30,31</sup>

The patients' characteristics and surgical procedures are presented in Table 1.

### 3.3 | Functional outcomes (main criteria)

Fifteen patients (6.6%) experienced diplopia after resection and orbit reconstruction, 1/33 in group A, 4/85 in group B, 8/75 in group C, and 2/35 in group D (Table 2). The symptom was evaluated by clinical examination with no objective measurement reported. In three patients the diplopia was secondary to direct lesions of the extraocular musculature, including two cases of direct surgical

lesion<sup>19,27</sup> and one case of tumor invasion of the inferior rectus muscle.<sup>27</sup>

Postoperative ectropion was diagnosed in 78 patients (42.6%), mainly in patients reconstructed with soft tissue (17/27), followed by reconstruction with alloplastic implants (34/79), bone graft (26/70), and bone free flaps (1/7) (Table 2). Secondary procedures were needed to correct the palpebral retraction in 17 patients of the group B and 7 patients of the group C. Ectropion was corrected with lateral or medial canthopexy, or by interposing a spreader graft.

Six cases of DVA were recorded, including three patients reconstructed with a free bone flap and one patient who received a soft-tissue reconstruction.<sup>31</sup> Two patients in group B developed a DVA secondary to local recurrence of adenoid cystic carcinoma with invasion of the extraocular muscles<sup>29</sup> and to postoperative ischemic retinopathy.<sup>15</sup>

### 3.4 | Secondary criteria

The aesthetic outcomes were assessed on postoperative photographs and by clinical examination during follow-up visits.<sup>7,18,22,26,27,31,35</sup> Four studies reported the use of several reviewers to assess the aesthetic parameters.<sup>7,16,18,19</sup> Two studies compared the orbital volume

TABLE 1 Demographic data of the patients and the surgical procedure used in the included studies.

Article	No. of patients	Recruitment period	Age, year ( $\pm$ SD)	Gender (M/F)	Follow-up, months ( $\pm$ SD)	Orbit reconstruction	Associated procedure
<i>Group A</i>		<i>n</i> = 33					
Iyer et al. <sup>13</sup>	7	2007–2008	57.2 ( $\pm$ 9.3)	5/2	6	TFL-IC: <i>n</i> = 7	—
Kraft et al. <sup>35</sup>	6	—	45.6 ( $\pm$ 23.9)	3/3	26.7 ( $\pm$ 13.6)	Serratus-rib: <i>n</i> = 6	—
Sampathirao et al. <sup>31</sup>	20 <sup>a</sup>	2004–2009	—	—	—	FFF: <i>n</i> = 14  TFL-IC: <i>n</i> = 9 Bony RF: <i>n</i> = 2 LD-Rib: <i>n</i> = 1	—
<i>Group B</i>		<i>n</i> = 85					
Zhang et al. <sup>28</sup>	6	2012–2014	56.1 ( $\pm$ 25.2)	4/2	24.1 ( $\pm$ 8.4)	3D Titanium Implant: <i>n</i> = 6	ALT: <i>n</i> = 4  FFF: <i>n</i> = 1 RA: <i>n</i> = 1
Jung et al. <sup>29</sup>	14	2003–2013	59.4 ( $\pm$ 12.6)	10/4	63.1 ( $\pm$ 27.5)	Titanium mesh: <i>n</i> = 2  Absorbable sheet: <i>n</i> = 12	0
Le Clerc et al. <sup>23</sup>	7	2013–2015	58.7 ( $\pm$ 11.5)	1/6	24 ( $\pm$ 18.4)	3D Titanium implant: <i>n</i> = 7	SD: <i>n</i> = 4  LD: <i>n</i> = 2 FT: <i>n</i> = 1
Motiee-Langroudi et al. <sup>36</sup>	10	2009–2010	49 ( $\pm$ 16.6)	8/2	35.9 ( $\pm$ 5.6)	Titanium mesh: <i>n</i> = 10	TFL: <i>n</i> = 10
Bianchi et al. <sup>12</sup>	1	1996–2008	78	1/0	90	Titanium mesh: <i>n</i> = 1	IC: <i>n</i> = 1
Trosman et al. <sup>16</sup>	12	2006–2015	55 ( $\pm$ 18.5)	3/9	48 ( $\pm$ 30.8)	Titanium mesh: <i>n</i> = 12	FFF: <i>n</i> = 12
Shipchandler et al. <sup>15</sup>	7	2005–2010	50.9 ( $\pm$ 23.3)	2/5	30 ( $\pm$ 25.6)	Titanium mesh: <i>n</i> = 7	FFF: <i>n</i> = 7
Zhu et al. <sup>27</sup>	12	2011–2018	55	6/6	—	Orbital plates: <i>n</i> = 11  Titanium mesh: <i>n</i> = 1	FFF: <i>n</i> = 11  ALT: <i>n</i> = 1
Dediol et al. <sup>22</sup>	7	2009–2012	57 ( $\pm$ 13.6)	6/1	21 ( $\pm$ 14.4)	3D Titanium implant: <i>n</i> = 7	ALT: <i>n</i> = 6  LD: <i>n</i> = 1
Kim et al. <sup>21</sup>	4	1993–2008	40 ( $\pm$ 7.1)	1/3	—	Titanium mesh	FT: <i>n</i> = 4
Hashikawa et al. <sup>26</sup>	5	1994–1999	64.8 ( $\pm$ 4.1)	3/2	72 ( $\pm$ 5.4)	Titanium mesh	RF: <i>n</i> = 5
<i>Group C</i>		<i>n</i> = 79					
Chen et al. <sup>18</sup>	9	1997–2005	54.3 ( $\pm$ 14.6)	—	10 ( $\pm$ 10.3)	Iliac: <i>n</i> = 4  Calvaria: <i>n</i> = 4 Mandible: <i>n</i> = 1	RA: <i>n</i> = 9

(Continues)

TABLE 1 (Continued)

Article	No. of patients	Recruitment period	Age, year ( $\pm$ SD)	Gender (M/F)	Follow-up, months ( $\pm$ SD)	Orbit reconstruction	Associated procedure
Cordeiro et al. <sup>19</sup>	14	1992–1997	51 ( $\pm$ 16.2)	8/6	21 ( $\pm$ 15.0)	Iliac: $n = 2$ Calvaria: $n = 6$ Rib: $n = 6$	RA: $n = 12$ TM: $n = 2$
Cenzi et al. <sup>17</sup>	5	1990–2005	50.6 ( $\pm$ 14.8)	3/2	60.2 ( $\pm$ 43.0)	Calvaria: $n = 5$	TM: $n = 5$
Bianchi et al. <sup>20</sup>	22	1996–2003	62.3 ( $\pm$ 13.0)	13/9	32 ( $\pm$ 31.0)	Iliac: $n = 22$	RA: $n = 22$
Bianchi et al. <sup>12</sup>	5	1996–2006	68.3 ( $\pm$ 13.0)	3/2	90	Iliac: $n = 5$	IC: $n = 5$
Cordeiro et al. <sup>7</sup>	22	1992–2006	—	—	—	Iliac: $n = 9$ Calvaria: $n = 7$ Rib: $n = 3$ Mandible: $n = 1$ Unknown: $n = 2$	RA: $n = 22$
Kim et al. <sup>21</sup>	2	1993–2008	67 ( $\pm$ 28.3)	2/0	—	Calvaria: $n = 2$	FT: $n = 2$
Group D	$n = 35$						
Jung et al. <sup>29</sup>	5	2003–2013	49.4 ( $\pm$ 17.5)	2/3	30 ( $\pm$ 24.5)	FL	0
Joo et al. <sup>30</sup>	22	2004–2011	54.2 ( $\pm$ 14.6)	16/6	6	FL	ALT: $n = 22$
Sampathirao et al. <sup>31</sup>	8	2004–2009	—	—	—	Fascia of the RA: $n = 6$ Prolene <sup>®</sup> : $n = 2$	RA: $n = 6$ RF: $n = 2$

Abbreviations: ALT, anterolateral thigh; F, female; FFF, fibula free flap; FL, fascia lata sling; FT, fascia temporalis pedicled flap; IC, iliac crest (free flap); LD, latissimus dorsi; M, male; n, number of patients; RA, rectus abdominis; RF, radial artery forearm; SD, scapulo-dorsal flap; TFL, tensor fascia lata; TM, temporalis muscle pedicled flap.

<sup>a</sup>Despite 26 patients included by the authors, the functional and aesthetic results were reported in 20 patients included in our analysis.

and the bony reliefs between the reconstructed hemiface and the normal side using 3D software on postoperative CT scans.<sup>27,28</sup> Dystopia interested 1/33 patient in group A,<sup>31</sup> none in group B, 5/79 patients of group C,<sup>7,18–20</sup> and 1/8 patients in group D.<sup>31</sup> Enophthalmos was assessed in 3/33 patients of group A,<sup>13,31</sup> 8/68 patients of group B,<sup>15,16,21,27</sup> 2/52 patients in group C,<sup>18</sup> and five cases out of 35 patients analyzed in group D.<sup>30,31</sup> Enophthalmos was not a functional or aesthetic concern for the patients and did not require a secondary procedure. The facial symmetry was evaluated clinically in 161 patients and indicated overall satisfactory results in studies (117 cases were considered as good results, 29 as fair, 8 were poor results, and 7 were unknown).

A postoperative infection occurred at the donor site in one patient of group A (TFL-IC flap), and one patient of group D (FL-ALT), and these were managed conservatively.<sup>13,30</sup> In group B, 5 patients who received a titanium mesh or an absorbable sheet with no associated flap developed a late infection, one required the removal of the material at 6 months and the reconstruction with a rib bone graft and a TM flap.<sup>29</sup> Two cases of infection

were reported in group C, one of which resolved with antibiotic therapy, while the second patient required additional procedures to debride the infected area.<sup>18,19</sup> Material exposure occurred in 17 patients of group B<sup>15,16,21,22,29,36</sup> and 2 patients of group C<sup>17</sup>; all the patients had a history of irradiation, except for one patient whose material was exposed after trauma. Eight cases occurred among the 14 patients reconstructed with an alloplastic material with no associated flap procedure.<sup>29</sup> The treatments were based on coverage with a local<sup>16,22,29,36</sup> or free flap,<sup>21</sup> sometimes combined with complete removal of the material.<sup>16,17,29</sup>

## 4 | DISCUSSION

Maxillary tumors are rare cancers and are often diagnosed at locally advanced stage due to late and non-specific symptoms. The reference treatment usually associates maxillectomy and adjuvant radiotherapy.<sup>3</sup> The current attitude in regard to oncological margins for sinuso-nasal tumors is organ preservation. Similar

TABLE 2 Assessment of diplopia and ectropion in the literature review.

Article	Number of diplopia	Ectropion		
		Incision approach	Number	Surgical revision
Group A	1/33		1/7	
Iyer et al. <sup>13</sup>	0/7	—	1/7	—
Kraft et al. <sup>35</sup>	0/6	—	—	—
Sampathirao et al. <sup>31</sup>	1/20	—	—	—
Group B	4/85		34/79	
Zhang et al. <sup>28</sup>	1/6	—	—	—
Jung et al. <sup>29</sup>	0/14	—	9/14	—
Le Clerc et al. <sup>23</sup>	0/7	WF: n = 7	3/7	1/3
Motiee-Langroudi et al. <sup>36</sup>	0/10	WF: n = 10	3/10	2/3
Bianchi et al. <sup>12</sup>	0/1	—	1/1	—
Trosman et al. <sup>16</sup>	0/12	WF: n = 7/ ELR: n = 5	6/12	6/6
Shipchandler et al. <sup>15</sup>	0/7	WF: n = 2/ ELR: n = 4 / unknown: n = 1	3/7	3/3
Zhu et al. <sup>27</sup>	2/12	—	8/12	4/8
Dediol et al. <sup>22</sup>	0/7	WF: n = 7	0/7	—
Kim et al. <sup>21</sup>	0/4	—	0/4	—
Hashikawa et al. <sup>26</sup>	1/5	WF: n = 5	1/5	1/1
Group C	8/75		26/70	
Chen et al. <sup>18</sup>	0/9	WF: n = 9	1/9	0/1
Cordeiro et al. <sup>19</sup>	1/14	—	10/14	6/10
Cenzi et al. <sup>17</sup>	0/5	—	—	—
Bianchi et al. <sup>20</sup>	3/22	—	5/22	—
Bianchi et al. <sup>12</sup>	0/5	—	1/5	1/1
Cordeiro et al. <sup>7</sup>	4/18	—	9/18	0/9
Kim et al. <sup>21</sup>	0/2	—	0/2	—
Group D	2/35		17/27	
Jung et al. <sup>29</sup>	0/5	—	2/5	—
Joo et al. <sup>30</sup>	1/22	WF: n = 22	15/22	—
Sampathirao et al. <sup>31</sup>	1/8	—	—	—

Abbreviations: ELR, extended lateral rhinotomy; n, number of patients; WF, Weber–Ferguson incision.

oncologic results were established for patients who underwent eye-sparing surgery or orbital exenteration in terms of 5-year survivals and local recurrence.<sup>37,38</sup> Although excision surgery and maxillary reconstruction are well codified, there are no recommendations in the current literature regarding orbit reconstruction.<sup>7,12,17–21</sup> This systematic review aimed to compare the techniques used for orbital floor reconstruction after total maxillectomy with respect to ocular functional and aesthetic parameters. A limited number of studies were found, as well as a great heterogeneity in the clinical parameters studied with a mostly subjective evaluation of the results. The mean follow-up ranged from 6 to 90 months, and a short follow-up could represent an issue when analyzing

the late complications, especially those related to postoperative radiotherapy (material exposure, infection, or resorption of the graft). We expressed our results by generating four groups, based on the variety of the reconstruction techniques regarding the use of vascularized versus non-vascularized tissue, rigid versus soft-tissue reconstruction, and autologous versus alloplastic materials for orbit reconstruction. When multiple techniques were combined (e.g., an alloplastic material and a soft-tissue or bone flap), we considered the technique that provided most of the support for the intraorbital content. However, it is obvious that the contribution of a vascularized bone flap adds greatly to the stability of the orbital framework and reduces the risk of secondary

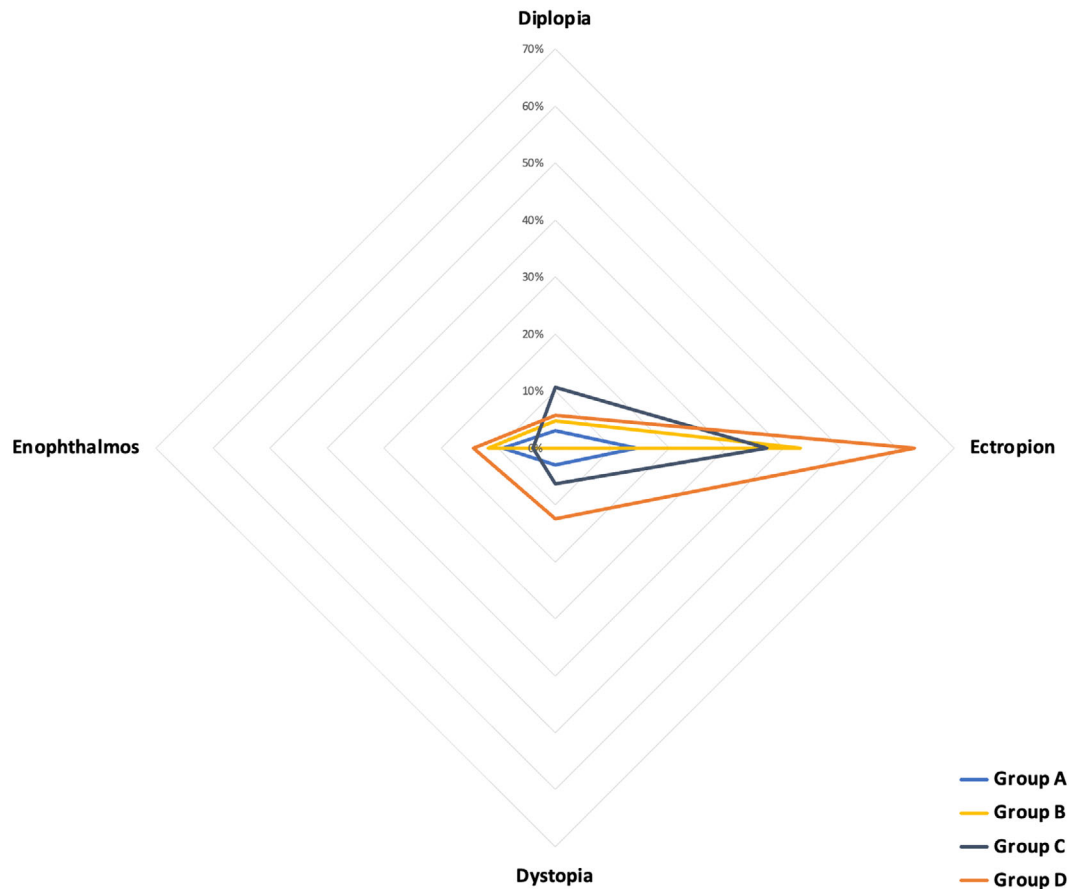


complications.<sup>15,16</sup> In this regard, the study by Jung et al. reported more complications (35.7% rate of infection and 57.1% rate of material exposure) in patients reconstructed with an alloplastic implant without an associated flap procedure.<sup>29</sup> Patients who did not undergo reconstruction after maxillectomy were excluded from the study, as the absence of repair is more likely to result in enophthalmos and dystopia.<sup>39</sup> Most reconstructions (71%) used alloplastic materials or bone grafts, while few studies referred to the use of a vascularized free bone flap for the orbit repair although these flaps appear to be the method of choice for maxillary reconstruction.<sup>4</sup> One of the explanations lies in the operative time required for large tumor resection and reconstruction.<sup>40</sup> Indeed, a long operative time is more likely to be associated with a risk of free flap failure in head and neck reconstruction.<sup>41</sup> Furthermore, some authors have argued that priority is given to fill the maxillary defect to allow timely initiation of complementary treatments, and to limit the significant systemic stress associated with bone reconstruction.<sup>30</sup> Finally, the use of a free bone or soft-tissue flap is usually preferred for the reconstruction of the lower framework, allowing restoration of speech and feeding, while orbit reconstruction can be achieved with other materials.

This systematic review revealed that postoperative ectropion was the most frequently observed complication (42.6% of patients) irrespective of the method of reconstruction. Although ectropion can have an aesthetic impact, it mostly has functional consequences with regard to the risk of exposure keratitis, decrease in visual acuity, epiphora, and chronic conjunctivitis. The cicatricial ectropion may be secondary to the frequent use of the Weber-Ferguson incision with subciliary extension for maxillary tumor extirpation.<sup>9</sup> Some authors favor use of the transconjunctival approach as an alternative to the subciliary incision in total maxillectomies.<sup>42</sup> Furthermore, the irradiation of the orbital-facial region is likely to be associated with tissue retraction, muscle atrophy, and skin dystrophy, favoring the occurrence of ectropion. The complication was more frequent in the group D of patients receiving a FL string without repair of the infraorbital rim (Figure 2). The infraorbital rim likely plays an important role in supporting the lower eyelid and the globe, and its accurate positioning may help prevent the development of ectropion, hypoglobus, and enophthalmos.<sup>27</sup> In their series, Joo et al. reported a high proportion of patients with substantial defects of the orbital rim and a high rate of postoperative ectropion (58.2%).<sup>30</sup> Various procedures can be combined for the reconstruction of ectropion in irradiated tissues including canthotomy, canthopexy, spreader graft, and lipofilling.<sup>43,44</sup> Diplopia was poorly reported and mostly associated with non-vascularized bone grafts (Figure 2), possibly enhanced by

the radiation-induced bone resorption. In the context of total maxillectomies, diplopia can have several etiologies: it may be secondary to the lack of rigid support resulting in ptosis of the orbital content. It may also be related to tumor extension or damage to the inferior rectus muscle during surgical resection and is in this context associated with an oculomotor disorder. Carcinologic involvement of the ocular musculature is usually an indication for orbital exenteration, and this scenario was not considered in our study.<sup>37</sup> It is likely that preservation of the infraorbital periosteum also prevents a number of complications including diplopia, extraocular muscle impairment, and enophthalmos. Unfortunately, the included studies rarely reported the extent of orbital resection, thus preventing us from addressing this issue. Furthermore, measurement of the diplopia was lacking, with the absence of an objective method of assessment. A full orthoptic preoperative and postoperative examination should be recommended in the context of oncological orbit reconstruction.

Dystopia and enophthalmos were also assessed, revealing more frequent occurrence in reconstructions using a flexible material such as FL (Figure 2). Nevertheless, the study did not reveal any difference in the occurrence of complications, whether the reconstruction was done with a FL alone or in combination with a soft-tissue flap. These data are in line with numerous studies that recommend a rigid reconstruction of orbit floor to ensure support of the orbital contents.<sup>31,39</sup> In a comparative study of rigid bone reconstruction and soft tissue repair with free tissue transfer, Sampathirao et al. found a significant association of eyeball malposition with soft tissue reconstruction, but no difference in terms of the functional outcome, eye movement, and visual acuity.<sup>31</sup> Enophthalmos can have multiple causes as it can be related to a change in the volume of the orbital frame but also to a loss of intraorbital fat and muscle volume secondary to radiotherapy. Some authors recommend slight overcorrection of the orbital floor reconstruction in a non-anatomical position to anticipate the volume loss related to radiotherapy.<sup>16,20</sup> Regarding orbital reconstruction in a non-oncological context (i.e., in traumatic injuries), many materials have been developed, albeit with no comprehensive guidelines for their use.<sup>45</sup> Resorbable sheets are mostly proposed for small fractures, while large fractures require alloplastic implants, depending on the teams' habits.<sup>46,47</sup> Autologous bone grafts no longer seem suitable owing the increased surgical time, the donor site morbidity, and an unpredictable resorption.<sup>48</sup> In a systematic review and meta-analysis comparing the materials used for orbital fracture repair, Bourry et al. have reported good functional and aesthetic results associated with porous polyethylene and titanium mesh for reconstruction of large defects.<sup>49</sup> The same authors



**FIGURE 2** Radar graph presenting the main postoperative ocular parameters according to the reconstruction techniques. [Color figure can be viewed at [wileyonlinelibrary.com](https://onlinelibrary.wiley.com/doi/10.1002/hed.27352)]

reported an 11% rate of diplopia and a 4.5% rate of enophthalmos after the primary repair in the 946 patients analyzed.<sup>49</sup> Nevertheless, in the context of maxillectomy, the challenge lies both in the orbit repair and in the complete closure between the bucco-nasal cavity and the orbit to ensure the oral functions and to avoid upward contamination of the orbital content by sinus microbial entities.

Even though our study is the first to investigate orbital reconstruction in Brown class III total maxillectomies, it suffers from some shortcomings. The first lies in the inclusion of case series with low level of evidence.<sup>50</sup> However, in the field of surgery, observational studies can provide valuable information regarding the benefits and risks of certain procedures when double-blind surgical trials are not possible.<sup>51</sup> Secondly, there was substantial heterogeneity in the methods used regarding the assessment of the functional and aesthetic parameters, almost with subjective clinical methods of measurements. Finally, the ophthalmological functional and aesthetic parameters were assessed only based on the reconstruction techniques. However, it is likely that the surgical resection itself plays an important role in the

occurrence of complications, and Brown class III maxillectomies include a wide range of orbital procedures regarding the excision of the infraorbital rim and the medial/lateral walls. Due to the lack of reported data related to the orbit defect, it was not possible to address this issue. Nevertheless, we assume that the large orbital defects were reconstructed using alloplastic implants or osteotomized bone grafts, whereas the use of free bone flaps was limited to the reconstruction of the orbital floor.

## 5 | CONCLUSION

Notwithstanding the quality and limitations of the literature, qualitative evaluation of the existent techniques used for orbital floor reconstruction after maxillectomy suggests that bone free flaps and alloplastic implants associated with free flaps represent good options regarding the postoperative ophthalmologic functional and aesthetic parameters. There is currently a lack of confidence in the available literature regarding the clinical benefits of use of an alloplastic material alone, an autologous

bone graft, or soft tissue reconstruction in terms of the risk of postoperative complications including material exposure and enophthalmos for orbital floor reconstruction in Brown class III maxillectomies.

### AUTHOR CONTRIBUTIONS

All the authors mentioned in this manuscript contributed to the work reported, have read and approved the final version of this manuscript, and agree to be accountable for all aspects of work ensuring integrity and accuracy. The authors contributed as follows: Conceptualization, Sophie Dugast, Julie Longis, and Hélios Bertin; Formal analysis, Sophie Dugast, Julie Longis and Hélios Bertin; Methodology, Jean-François Huon, and Hélios Bertin; Writing – Original draft preparation, Sophie Dugast, Marine Anquetil, Benoit Piot, and Pierre Corre; Writing – Review and editing, Sophie Dugast, and Hélios Bertin.

### ACKNOWLEDGMENTS

The authors thank Mrs Sophie Domingues for her careful reading and correction of the English version of this manuscript. The authors thank Mrs Sandrine Coudol for her methodological support.

### FUNDING INFORMATION

This research was supported by Fondation les Gueules Cassées (2018–51), and Nantes University Hospital. The sponsors had no role in the study design, or in the writing or the submission of this manuscript.

### CONFLICT OF INTEREST STATEMENT

The authors declare no conflicts of interest.

### DATA AVAILABILITY STATEMENT

The datasets used and analyzed during the current study are available from the corresponding author on reasonable request.

### ETHICS APPROVAL STATEMENT

Authors declare that human ethics approval was not applicable for this study.

### ORCID

Hélios Bertin  <https://orcid.org/0000-0002-0546-079X>

### REFERENCES

- Dhanani R, Faisal M, Shahid H, Malik KI, Jamshed A, Hussain R. Outcomes of management of sinonasal malignancies at a dedicated cancer institution: a retrospective study. *Ann Maxillofac Surg*. 2021;11(1):115-120. doi:10.4103/ams.ams\_16\_21
- Maghami E, Kraus DH. Cancer of the nasal cavity and paranasal sinuses. *Expert Rev Anticancer Ther*. 2004;4(3):411-424. doi:10.1586/14737140.4.3.411
- Ashraf M, Biswas J, Dam A, et al. Results of treatment of squamous cell carcinoma of maxillary sinus: a 26-year experience. *World J Oncol*. 2010;1(1):28-34. doi:10.4021/wjon2010.02.191w
- Brown JS, Shaw RJ. Reconstruction of the maxilla and midface: introducing a new classification. *Lancet Oncol*. 2010;11(10):1001-1008. doi:10.1016/S1470-2045(10)70113-3
- Santamaria E, de la Concha E. Lessons learned from delayed versus immediate microsurgical reconstruction of complex maxillectomy and midfacial defects: experience in a tertiary center in Mexico. *Clin Plast Surg*. 2016;43(4):719-727. doi:10.1016/j.cps.2016.05.011
- Hanasono MM, Silva AK, Yu P, Skoracki RJ. A comprehensive algorithm for oncologic maxillary reconstruction. *Plast Reconstr Surg*. 2013;131(1):47-60. doi:10.1097/PRS.0b013e3182729e73
- Cordeiro PG, Chen CM. A 15-year review of midface reconstruction after total and subtotal maxillectomy: part I. Algorithm and outcomes. *Plast Reconstr Surg*. 2012;129(1):124-136. doi:10.1097/PRS.0b013e318221dca4
- Brown JS, Rogers SN, McNally DN, Boyle M. A modified classification for the maxillectomy defect. *Head Neck*. 2000;22(1):17-26. doi:10.1002/(sici)1097-0347(200001)22:1<17::aid-hed4>3.0.co;2-2
- Sweeney AR, Walker B, Bhrany AD, Chang SH, Jian-Amadi A. Ophthalmic changes following maxillectomy with or without postoperative radiation therapy. *J Craniofac Surg*. 2019;30(5):1448-1451. doi:10.1097/SCS.0000000000005437
- Moya-Plana A, Veyrat M, Honart JF, et al. Reconstruction of maxillectomy and midfacial defects using latissimus dorsi-scapular free flaps in a comprehensive cancer center. *Oral Oncol*. 2019;99:104468. doi:10.1016/j.oraloncology.2019.104468
- Brown JS. Deep circumflex iliac artery free flap with internal oblique muscle as a new method of immediate reconstruction of maxillectomy defect. *Head Neck*. 1996;18(5):412-421. doi:10.1002/(SICI)1097-0347(199609/10)18:5<412::AID-HED4>3.0.CO;2-8
- Bianchi B, Ferri A, Ferrari S, Copelli C, Boni P, Sesenna E. Iliac crest free flap for maxillary reconstruction. *J Oral Maxillofac Surg*. 2010;68(11):2706-2713. doi:10.1016/j.joms.2010.01.008
- Iyer S, Chatni S, Kuriakose MA. Free tensor fascia lata-iliac crest osteomusculocutaneous flap for reconstruction of combined maxillectomy and orbital floor defect. *Ann Plast Surg*. 2012;68(1):52-57. doi:10.1097/SAP.0b013e31820ebc19
- Wilkman T, Husso A, Lassus P. Clinical comparison of scapular, fibular, and iliac crest osseal free flaps in maxillofacial reconstructions. *Scand J Surg*. 2019;108(1):76-82. doi:10.1177/1457496918772365
- Shipchandler TZ, Waters HH, Knott PD, Fritz MA. Orbitomaxillary reconstruction using the layered fibula osteocutaneous flap. *Arch Facial Plast Surg*. 2012;14(2):110-115. doi:10.1001/archfacial.2011.1329
- Trosman SJ, Haffey TM, Couto RA, Fritz MA. Large orbital defect reconstruction in the setting of globe-sparing maxillectomy: the titanium hammock and layered fibula technique. *Microsurgery*. 2018;38(4):354-361. doi:10.1002/micr.30199
- Cenzi R, Carinci F. Calvarial bone grafts and temporalis muscle flap for midfacial reconstruction after maxillary tumor resection: a long-term retrospective evaluation of 17 patients. *J Craniofac Surg*. 2006;17(6):1092-1104. doi:10.1097/01.scs.0000246505.86721.54
- Chen CM, Cordeiro PG. The tongue-in-groove technique for orbital floor reconstruction after maxillectomy. *Plast Reconstr*

- Surg.* 2008;121(1):225-232. doi:[10.1097/01.prs.0000293865.28595.75](https://doi.org/10.1097/01.prs.0000293865.28595.75)
19. Cordeiro PG, Santamaria E, Kraus DH, Strong EW, Shah JP. Reconstruction of total maxillectomy defects with preservation of the orbital contents. *Plast Reconstr Surg.* 1998;102(6):1874-1884; discussion 1885-1887. doi:[10.1097/00006534-199811000-00011](https://doi.org/10.1097/00006534-199811000-00011)
  20. Bianchi B, Bertolini F, Ferrari S, Sesenna E. Maxillary reconstruction using rectus abdominis free flap and bone grafts. *Br J Oral Maxillofac Surg.* 2006;44(6):526-530. doi:[10.1016/j.bjoms.2005.10.007](https://doi.org/10.1016/j.bjoms.2005.10.007)
  21. Kim JYS, Buck DW, Johnson SA, Butler CE. The temporoparietal fascial flap is an alternative to free flaps for orbitomaxillary reconstruction. *Plast Reconstr Surg.* 2010;126(3):880-888. doi:[10.1097/PRS.0b013e3181e3b6f0](https://doi.org/10.1097/PRS.0b013e3181e3b6f0)
  22. Dediol E, Uglešić V, Zubčić V, Knežević P. Brown class III maxillectomy defects reconstruction with prefabricated titanium mesh and soft tissue free flap. *Ann Plast Surg.* 2013;71(1):63-67. doi:[10.1097/SAP.0b013e318246e895](https://doi.org/10.1097/SAP.0b013e318246e895)
  23. Le Clerc N, Baudouin R, Carlevan M, Khoueir N, Verillaud B, Herman P. 3D titanium implant for orbital reconstruction after maxillectomy. *J Plast Reconstr Aesthet Surg.* 2020;73(4):732-739. doi:[10.1016/j.bjps.2019.11.014](https://doi.org/10.1016/j.bjps.2019.11.014)
  24. Liu BY, Cao G, Dong Z, Chen W, Xu JK, Guo T. The application of 3D-printed titanium mesh in maxillary tumor patients undergoing total maxillectomy. *J Mater Sci Mater Med.* 2019;30(11):125. doi:[10.1007/s10856-019-6326-7](https://doi.org/10.1007/s10856-019-6326-7)
  25. Sun Q, Soh HY, Zhang WB, et al. Long-term effect of individualized titanium mesh in orbital floor reconstruction after maxillectomy. *Laryngoscope.* 2021;131(10):2231-2237. doi:[10.1002/lary.29569](https://doi.org/10.1002/lary.29569)
  26. Hashikawa K, Tahara S, Ishida H, et al. Simple reconstruction with titanium mesh and radial forearm flap after globe-sparing total maxillectomy: a 5-year follow-up study. *Plast Reconstr Surg.* 2006;117(3):963-967. doi:[10.1097/01.prs.0000200623.91956.66](https://doi.org/10.1097/01.prs.0000200623.91956.66)
  27. Zhu B, Han M, Heaton C, Park AM, Seth R, Knott PD. Assessing free flap reconstruction accuracy of the midface and orbit using computer-aided modeling software. *Facial Plast Surg Aesthet Med.* 2020;22(2):93-99. doi:[10.1089/fpsam.2019.29013.zhu](https://doi.org/10.1089/fpsam.2019.29013.zhu)
  28. Zhang WB, Mao C, Liu XJ, Guo CB, Yu GY, Peng X. Outcomes of orbital floor reconstruction after extensive maxillectomy using the computer-assisted fabricated individual titanium mesh technique. *J Oral Maxillofac Surg.* 2015;73(10):2065-2115. doi:[10.1016/j.joms.2015.06.171](https://doi.org/10.1016/j.joms.2015.06.171)
  29. Jung BK, Yun IS, Lee WJ, Lew DH, Choi EC, Lee DW. Orbital floor reconstruction using a tensor fascia lata sling after total maxillectomy. *J Craniomaxillofac Surg.* 2016;44(5):648-653. doi:[10.1016/j.jcms.2016.01.020](https://doi.org/10.1016/j.jcms.2016.01.020)
  30. Joo YH, Cho KJ, Park JO, Kim MS. Usefulness of the anterolateral thigh flap with vascularized fascia lata for reconstruction of orbital floor and nasal surface after total maxillectomy. *Laryngoscope.* 2013;123(9):2125-2130. doi:[10.1002/lary.23797](https://doi.org/10.1002/lary.23797)
  31. Sampathirao LMCSR, Thankappan K, Duraisamy S, et al. Orbital floor reconstruction with free flaps after maxillectomy. *Craniomaxillofac Trauma Reconstr.* 2013;6(2):99-106. doi:[10.1055/s-0033-1343777](https://doi.org/10.1055/s-0033-1343777)
  32. Hutton B, Salanti G, Caldwell DM, et al. The PRISMA extension statement for reporting of systematic reviews incorporating network meta-analyses of health care interventions: checklist and explanations. *Ann Intern Med.* 2015;162(11):777-784. doi:[10.7326/M14-2385](https://doi.org/10.7326/M14-2385)
  33. OCEBM. *Levels of Evidence Working Group — Centre for Evidence-Based Medicine (CEBM).* University of Oxford; 2011 <https://www.cebm.ox.ac.uk/resources/levels-of-evidence/ocebml-levels-of-evidence>
  34. Mh M, Sultan S, Haffar S, Bazerbachi F. Methodological quality and synthesis of case series and case reports. *BMJ Evid Based Med.* 2018;23(2):60-63. doi:[10.1136/bmjebm-2017-110853](https://doi.org/10.1136/bmjebm-2017-110853)
  35. Kraft CT, Hanasono MM, Skoracki RJ. The free serratus-rib flap for orbital floor reconstruction after oncologic resection. *Ann Plast Surg.* 2020;84(4):409-412. doi:[10.1097/SAP.0000000000002052](https://doi.org/10.1097/SAP.0000000000002052)
  36. Motiee-Langroudi M, Harirchi I, Amali A, Jafari M. Reconstruction of midface and orbital wall defects after maxillectomy and orbital content preservation with titanium mesh and fascia lata: 3-year follow-up. *J Oral Maxillofac Surg.* 2015;73(12):2447-2455. doi:[10.1016/j.joms.2015.08.011](https://doi.org/10.1016/j.joms.2015.08.011)
  37. Suárez C, Ferlito A, Lund VJ, et al. Management of the orbit in malignant sinonasal tumors. *Head Neck.* 2008;30(2):242-250. doi:[10.1002/hed.20736](https://doi.org/10.1002/hed.20736)
  38. Imola MJ, Schramm VL. Orbital preservation in surgical management of sinonasal malignancy. *Laryngoscope.* 2002;112(8 Pt 1):1357-1365. doi:[10.1097/00005537-200208000-00007](https://doi.org/10.1097/00005537-200208000-00007)
  39. Stern SJ, Goepfert H, Clayman G, Byers R, Wolf P. Orbital preservation in maxillectomy. *Otolaryngol Head Neck Surg.* 1993;109(1):111-115. doi:[10.1177/019459989310900120](https://doi.org/10.1177/019459989310900120)
  40. Lindeborg MM, Puram SV, Sethi R, et al. Predictive factors for prolonged operative time in head and neck patients undergoing free flap reconstruction. *Am J Otolaryngol.* 2020;41(2):102392. doi:[10.1016/j.amjoto.2020.102392](https://doi.org/10.1016/j.amjoto.2020.102392)
  41. Wang KY, Lin YS, Chen LW, Yang KC, Huang WC, Liu WC. Risk of free flap failure in head and neck reconstruction: analysis of 21,548 cases from a nationwide database. *Ann Plast Surg.* 2020;84:S3-S6. doi:[10.1097/SAP.0000000000002180](https://doi.org/10.1097/SAP.0000000000002180)
  42. Goyal A, Tyagi I, Jain S, Syal R, Singh AP, Kapila R. Transconjunctival incision for total maxillectomy: an alternative for subciliary incision. *Br J Oral Maxillofac Surg.* 2011;49(6):442-446. doi:[10.1016/j.bjoms.2010.07.002](https://doi.org/10.1016/j.bjoms.2010.07.002)
  43. Tarallo M, Rizzo MI, Monarca C, Fanelli B, Parisi P, Scuderi N. Optimal care for eyelid contraction after radiotherapy: case report and literature review. *J Oral Maxillofac Surg.* 2012;70(10):2459-2465. doi:[10.1016/j.joms.2011.10.017](https://doi.org/10.1016/j.joms.2011.10.017)
  44. Hammond SE, Samuels S, Thaller S. Filling in the details: a review of lipofilling of radiated tissues in the head and neck. *J Craniomaxillofac Surg.* 2019;30(3):667-671. doi:[10.1097/SCS.0000000000005107](https://doi.org/10.1097/SCS.0000000000005107)
  45. Crozet A, Lebranchu P, Vabre B, et al. Management of orbital floor fractures in France: results of a national online survey. *J Stomatol Oral Maxillofac Surg.* 2023;124(3):101389. doi:[10.1016/j.jormas.2023.101389](https://doi.org/10.1016/j.jormas.2023.101389)
  46. Christensen BJ, Zaid W. Inaugural survey on practice patterns of orbital floor fractures for American Oral and maxillofacial surgeons. *J Oral Maxillofac Surg.* 2016;74(1):105-122. doi:[10.1016/j.joms.2015.09.023](https://doi.org/10.1016/j.joms.2015.09.023)

47. Koh V, Chiam N, Sundar G. Survey of common practices among oculofacial surgeons in the Asia-Pacific region: management of orbital floor blowout fractures. *Craniomaxillofac Trauma Reconstr.* 2014;7(3):197-202. doi:[10.1055/s-0034-1371774](https://doi.org/10.1055/s-0034-1371774)
48. Al-Sukhun J, Lindqvist C. A comparative study of 2 implants used to repair inferior orbital wall bony defects: autogenous bone graft versus bioresorbable poly-L/DL-Lactide [P(L/DL)LA 70/30] plate. *J Oral Maxillofac Surg.* 2006;64(7):1038-1048. doi:[10.1016/j.joms.2006.03.010](https://doi.org/10.1016/j.joms.2006.03.010)
49. Bourry M, Hardouin JB, Fauvel F, Corre P, Lebranchu P, Bertin H. Clinical evaluation of the efficacy of materials used for primary reconstruction of orbital floor defects: meta-analysis. *Head Neck.* 2021;43(2):679-690. doi:[10.1002/hed.26518](https://doi.org/10.1002/hed.26518)
50. Murad MH. Clinical practice guidelines: a primer on development and dissemination. *Mayo Clin Proc.* 2017;92(3):423-433. doi:[10.1016/j.mayocp.2017.01.001](https://doi.org/10.1016/j.mayocp.2017.01.001)
51. Knight SR. The value of systematic reviews and meta-analyses in surgery. *Eur Surg Res.* 2021;62(4):221-228. doi:[10.1159/000519593](https://doi.org/10.1159/000519593)

**How to cite this article:** Dugast S, Longis J, Anquetil M, et al. Reconstruction techniques of the orbit after Brown class III maxillectomy: A systematic review. *Head & Neck.* 2023;45(6):1581-1593. doi:[10.1002/hed.27352](https://doi.org/10.1002/hed.27352)

## APPENDIX A

TABLE A1 Assessment of the quality of the included studies.

Reference (first author, year)	OCEBM	MQAT					
		Selection	Ascertainment	Outcome	Follow-up	Reporting	Overall
Bianchi, 2006 <sup>20</sup>	4	Moderate	Low	Low	High	High	Moderate
Bianchi, 2010 <sup>12</sup>	4	Moderate	Low	Low	High	High	Moderate
Cenzi, 2006 <sup>17</sup>	4	Moderate	Low	Low	High	High	Moderate
Chen, 2008 <sup>18</sup>	4	Moderate	Moderate	Low	Moderate	High	Low
Cordeiro, 1998 <sup>19</sup>	4	Moderate	Moderate	Low	High	High	High
Cordeiro, 2012 <sup>7</sup>	4	High	Moderate	Low	Moderate	High	High
Dediol, 2013 <sup>22</sup>	4	Moderate	Low	Low	Moderate	High	Low
Hashikawa, 2006 <sup>26</sup>	4	Moderate	Low	Low	High	High	Moderate
Iyer, 2012 <sup>13</sup>	4	Low	High	Low	High	High	High
Joo, 2013 <sup>30</sup>	4	Moderate	Moderate	Low	Low	High	Low
Jung, 2016 <sup>29</sup>	4	Moderate	Low	Low	High	High	Moderate
Kim, 2010 <sup>21</sup>	4	High	Low	Low	High	High	High
Kraft, 2020 <sup>35</sup>	4	High	Moderate	Low	High	High	High
Le Clerc, 2020 <sup>23</sup>	4	High	Low	Low	High	High	High
Motiee-Langroudi, 2015 <sup>36</sup>	4	Moderate	Low	Low	High	High	Moderate
Sampathirao, 2013 <sup>31</sup>	4	Moderate	Moderate	Low	High	High	High
Shipchandler, 2012 <sup>15</sup>	4	Moderate	Low	Low	High	High	Moderate
Trosman, 2018 <sup>16</sup>	4	High	Moderate	Low	High	High	High
Zhang, 2015 <sup>28</sup>	4	Moderate	High	Low	High	High	High
Zhu, 2020 <sup>27</sup>	4	Moderate	High	Low	High	High	High