



HAL
open science

Electromechanical delay measured during a voluntary contraction should be interpreted with caution

François Hug, Lilian Lacourpaille, Antoine Nordez

► **To cite this version:**

François Hug, Lilian Lacourpaille, Antoine Nordez. Electromechanical delay measured during a voluntary contraction should be interpreted with caution. *Muscle & Nerve*, 2011, 44 (5), pp.838-838. <10.1002/mus.22139>. <hal-03409803>

HAL Id: hal-03409803

<https://nantes-universite.hal.science/hal-03409803v1>

Submitted on 30 Aug 2023

HAL is a multi-disciplinary open access archive for the deposit and dissemination of scientific research documents, whether they are published or not. The documents may come from teaching and research institutions in France or abroad, or from public or private research centers.

L'archive ouverte pluridisciplinaire **HAL**, est destinée au dépôt et à la diffusion de documents scientifiques de niveau recherche, publiés ou non, émanant des établissements d'enseignement et de recherche français ou étrangers, des laboratoires publics ou privés.



HAL Authorization

ELECTROMECHANICAL DELAY MEASURED DURING A VOLUNTARY CONTRACTION SHOULD BE INTERPRETED WITH CAUTION

Electromechanical delay (EMD) is the time lag between muscle activation and muscle force production. It reflects both electrochemical processes (i.e., synaptic transmission, propagation of the action potential, excitation–contraction coupling) and mechanical processes (i.e., force transmission along the active and passive parts of the series elastic component).¹ Consequently, it has been often used (more than 100 articles in PubMed) to evaluate muscle function, such as during fatigue tasks, in response to training programs, after anterior cruciate ligament reconstruction, and in patients with neuropathy or myopathy.

EMD can be measured during voluntary, reflex, or electrically induced contraction. It should be considered a valid tool for evaluation of muscle function only if it is not influenced by methodological artifacts. In our opinion, EMD measurements performed during voluntary contraction fail to meet this criterion, mainly because the electromyographic (EMG) electrode location may greatly influence detection of onset of muscle activation. In fact, because the onset of force production is due to the first recruited muscle fibers,² it is crucial to detect precisely the onset of activation from these fibers. However, the use of classical EMG recordings, in which one pair of electrodes is placed somewhere between the motor point and the tendon, does not allow this to occur. Assuming a muscle fiber conduction velocity of 4 m/s,³ the propagation of the action potential from the motor point to a pair of electrodes placed 2 cm distal to the motor point would be 5 ms (in a fusiform muscle), which constitutes a relatively high error for EMD values between 40 and 60 ms.¹ Also, due to the spatial heterogeneity in muscle recruitment,⁴ one would expect a non-uniform onset of activation within the muscle. In other words, intra- and intersubject variations in EMD could be due in part (or totally) to differences in electrode location.

To illustrate this drawback, we detected the onset of muscle activation from surface EMG recorded with an electrode array (64 channels; EMG-USB; LISIN-Ottino

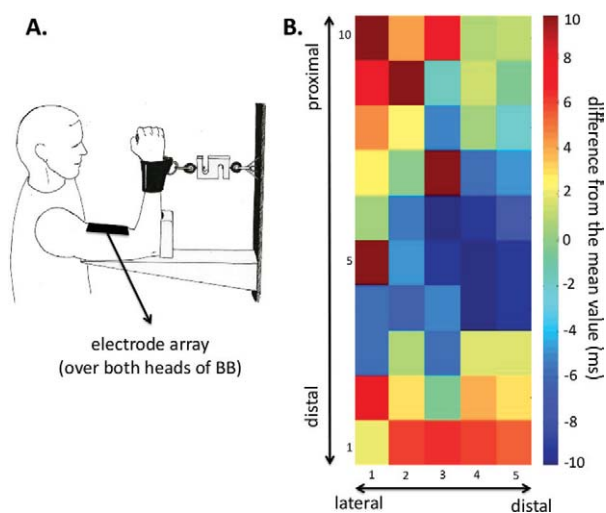


FIGURE 1. Experimental setup (A) and results (B). (A) The subject was seated upright. The angle between the upper arm and the forearm was fixed at 90°. He performed isometric elbow flexions as quickly as possible. (B) Electromyographic signals were amplified ($\times 500$), bandpass filtered (10–500 Hz), and digitized at 4096 Hz. The onset of EMG activity was automatically detected (threshold = 2 standard deviations beyond mean of baseline activity) and visually checked. The differences from the mean value calculated over 50 EMG channels are depicted. Note that the most proximal and distal lines of channels are not depicted. [Color figure can be viewed in the online issue, which is available at wileyonlinelibrary.com.]

Bioelettronica, Italy) during an isometric elbow flexion performed as quickly as possible. The results showed high variability in the onset times depending on the electrode location (up to 20 ms; Fig. 1). Because the use of electrode arrays would seem appealing, it does not totally solve the drawback just highlighted. The reason for this is that it mainly provides information from motor unit potentials (MUPs) recorded from the surface, where high-threshold motor units are predominant,⁵ and it cannot be used in all the synergist muscles involved in the task (e.g., deep muscles).

In conclusion, for a proper interpretation of changes in EMD (across subjects and across time), EMD should be measured during electrically induced contraction by taking into account the difference between the stimulation artifact (very easy to detect) and the onset of force

production. In combination with the detection of the onset of muscle fascicle and/or myotendinous junction motion using very high-frame-rate ultrasound^{2,6} or accelerometers,⁷ EMD may be proved to be a useful tool for evaluation of muscle function and monitoring changes induced by neuromuscular disease. Further clinical studies are needed to test the reliability of this technique in patients.

François Hug, PhD

Lilian Lacourpaille, MSc

Antoine Nordez, PhD

Laboratoire "Motricité, Interactions, Performance",
University of Nantes, Nantes, France

1. Cavanagh PR, Komi PV. Electromechanical delay in human skeletal muscle under concentric and eccentric contractions. *Eur J Appl Physiol Occup Physiol* 1979;42:159–163.
2. Nordez A, Gallot T, Catheline S, Guével A, Cornu C, Hug F. Electromechanical delay revisited using very high frame rate ultrasound. *J Appl Physiol* 2009;106:1970–1975.
3. Moritani T, Stegeman D, Merletti R. Basic physiology and biophysics of EMG signal generation. In: Merletti R, Parker P, editors. *Electromyography physiology engineering and noninvasive applications*. Hoboken, NJ: Wiley-IEEE; 2004. p 1–25.
4. Holtermann A, Roeleveld K, Karlsson JS. Inhomogeneities in muscle activation reveal motor unit recruitment. *J Electromyogr Kinesiol* 2005;15:131–137.
5. Johnson MA, Polgar J, Weightman D, Appleton D. Data distribution of fibre types in thirty-six human muscles. *J Neurol Sci* 1973;18:111–129.
6. Hug F, Gallot T, Catheline S, Nordez A. Electromechanical delay in biceps brachii assessed by ultrafast ultrasonography. *Muscle Nerve* 2011;43:441–443.
7. Sasaki K, Sasaki T, Ishii N. Acceleration and force reveal different mechanisms of electromechanical delay. *Med Sci Sport Exerc* 2011; 43:1200–1206

PREDNISONE CAN WORSEN ATAXIC NEUROPATHY WITH ANTI-DISIALOSYL IgM ANTIBODIES

The clinical picture of chronic sensory ataxic neuropathy with paraprotein in which IgM antibodies react with gangliosides sharing the terminal epitope NeuAc(α 2–8) NeuAc(α 2–3)^{1–4} has been referred to by the acronym CANOMAD when ophthalmoplegia and cold agglutinins are also present. Data on the response to treatment are limited to the description of single cases, and no therapeutic consensus has yet been reached.^{2,5–9}

A 50-year-old man was referred with a 7-year history of progressive unsteady gait. Clinical examination showed sensory loss affecting mainly proprioceptive and joint position sense, areflexia, and gait ataxia. His strength was normal. Electrophysiological studies showed global absence of sensory nerve action potentials. An enzyme-linked immunosorbent assay (ELISA) demonstrated antibodies against GD1b, GD3, GQ1b, GT1b, GM3, and GM1 gangliosides of the IgM class, confirmed by thin-layer chromatography that demonstrated additional reactivity against GM2. The whole reactivity cannot be explained by a single antibody, but it is similar

to other reported cases.^{2,7,10} An IgM monoclonal protein kappa light chain type was detected, and the reactivity to gangliosides corresponded to the same kappa light chain. Cold agglutinins were not tested.

The patient was initially treated with monthly intravenous immunoglobulin (IVIg) infusions (0.4 g/kg/day for 5 days) for 2 months, but with no improvement. During the next 2 years, he was treated successively with plasma exchange, azathioprine, methotrexate, and rituximab, but with no significant clinical benefit. Anti-ganglioside antibodies remained at similar titers. Treatment was then begun with oral prednisone 60 mg/day. One week after starting prednisone the patient had severe neurological deterioration consisting of global anesthesia, inability to walk independently, dysarthria, dysphagia, and diplopia. Ocular examination showed slow saccades and limited adduction of the left eye (Fig. 1B). Right ankle dorsiflexion weakness was noted (Fig. 1D and E). Neurophysiological study showed motor conduction block in the right fibular nerve with proximal stimulation (Fig. 1F). Further neurophysiological studies showed slowing of motor nerve conduction velocity in the ulnar and fibular nerves, and prolonged distal motor latency in the median nerve, consistent with a demyelinating process (Fig. 1G). A rise in anti-ganglioside antibody titers was detected (Fig. 1A). The patient received monthly IVIg infusions, and symptoms ameliorated (Fig. 1C) and anti-ganglioside antibody titers decreased (Fig. 1A).

Herein we have reported the case of a patient with chronic ataxic neuropathy with anti-disialosyl IgM antibodies who had severe worsening after corticosteroid treatment, and evolved with a clinical picture consistent with CANOMAD. A negative response of multifocal motor neuropathy to steroids is well known, but it has not been consistently observed in any other dysimmune neuropathies.^{11,12} Rapid functional improvement in motor neuropathies associated with IgM may occur with IVIg therapy, and the improvement is associated with reduction in the levels of IgM autoantibodies. Furthermore, worsening can be associated with a rise in anti-ganglioside antibody titers.¹³ Siddiqui et al. reported a case of chronic ataxic neuropathy in which the IgM band and antibodies against a disialosyl epitope were identified 6 years after the diagnosis, coinciding with a decrease in response to IVIg.¹⁴ In our patient, clinical worsening after prednisone treatment was associated with a rise in anti-ganglioside antibody titers, supporting a role for these antibodies in the pathogenesis of the disease.

We are unaware of other cases of chronic sensory ataxic neuropathy with anti-disialosyl IgM antibodies in whom steroid therapy worsened the clinical status and induced the CANOMAD syndrome. We believe that caution should be exercised when considering prednisone treatment for this condition.

Carmen Paradas, MD^{1,2}

Yolanda Morgado, MD³

Eduard Gallardo, PhD^{2,4}

Cándido Juarez, MD⁵

Ricard Rojas-García, MD^{2,6}

Supported by Research Grant (P109/1964) from the Fondo Investigación Sanitaria, Instituto Salud Carlos III.