



HAL
open science

A Gel Pad Designed to Measure Muscle Volume Using Freehand 3-Dimensional Ultrasonography

Julien Thomare, Lilian Lacourpaille, Peter Mcnair, Marion Crouzier, Richard Ellis, Antoine Nordez

► **To cite this version:**

Julien Thomare, Lilian Lacourpaille, Peter Mcnair, Marion Crouzier, Richard Ellis, et al.. A Gel Pad Designed to Measure Muscle Volume Using Freehand 3-Dimensional Ultrasonography. *Journal of Ultrasound in Medicine*, 2021, 40 (6), pp.1245-1250. 10.1002/jum.15490 . hal-03298657

HAL Id: hal-03298657

<https://nantes-universite.hal.science/hal-03298657>

Submitted on 20 Apr 2023

HAL is a multi-disciplinary open access archive for the deposit and dissemination of scientific research documents, whether they are published or not. The documents may come from teaching and research institutions in France or abroad, or from public or private research centers.

L'archive ouverte pluridisciplinaire **HAL**, est destinée au dépôt et à la diffusion de documents scientifiques de niveau recherche, publiés ou non, émanant des établissements d'enseignement et de recherche français ou étrangers, des laboratoires publics ou privés.

A Gel Pad Designed to Measure Muscle Volume Using Freehand 3-Dimensional Ultrasonography

Julien Thomare, MSc, Lilian Lacourpaille, PhD, Peter J. McNair, PhD, PT, Marion Crouzier, PhD, PT, Richard Ellis, PhD, PT, Antoine Nordez, PhD 

We developed an innovative gel pad that covers the entire lower leg to remove artifacts due to the pressure of the transducer in freehand 3-dimensional ultrasonography. In comparison to the reference method in water, this study showed that this new method was valid (bias, 3.4 mL; limit of agreement, 7.7 mL for a volume of ≈ 220 mL) and reliable (coefficient of variation, $<1.1\%$) for the measurement of gastrocnemius medialis muscle volume. Considering that it is easier to use than the water tank technique, it has much promise for volumetric measurement of many muscles.

Key Words—freehand 3-dimensional ultrasonography; muscle volume; reliability; standoff pad; validity; water tank

Received April 5, 2020, from the Université de Nantes, Movement, Interactions, and Performance Laboratory, Nantes, France (J.T., L.L., M.C., A.N.); Health and Rehabilitation Research Institute, Faculty of Health and Environmental Sciences, Auckland University of Technology, Auckland, New Zealand (P.J.M., R.E., A.N.); and Institut Universitaire de France, Paris, France (A.N.). Manuscript accepted for publication July 26, 2020.

This study was funded by funded by the International French Society of Biomechanics (mobility grant) and the Region des Pays de la Loire (Quantification of the Elasticity of Biological Tissues project, number 2015-09035). The gel pad was submitted for a patent on October 4, 2019 (FR1911014).

Address correspondence to Antoine Nordez, PhD, Movement, Interactions, and Performance Laboratory, EA 4334, University of Nantes, 25 Bis Boulevard Guy Mollet, BP 72206, 44322 Nantes, France.

E-mail: antoine.nordez@univ-nantes.fr

Abbreviations

3D, 3-dimensional; 3DUS, 3-dimensional ultrasonography; CV, coefficient of variation; GM, gastrocnemius medialis; MRI, magnetic resonance imaging; SEM, standard error of measurements; US, ultrasonography

Muscle volume assessments are very important for diagnosis, assessments of interventions, and descriptions of normal and pathologic growth.^{1–3} Currently, magnetic resonance imaging (MRI) is the “reference standard” for in vivo muscular volume measurement.⁴ However, it remains expensive, is difficult to access, and requires long acquisition times without motion while being within a relatively enclosed space, which, for some people, is uncomfortable and claustrophobic in the magnet. Freehand 3-dimensional ultrasonography (3DUS) is an alternative method that has been validated when compared to MRI measurements.⁵ This is a low-cost method, as it requires only a conventional 2-dimensional ultrasonography (US) scanner and a tracking system to measure the 3-dimensional (3D) position of the transducer,^{6,7} both of which are much less in cost compared to an MRI unit.

However, soft tissue deformation induced by the transducer sweeps generates a biased 3D reconstruction and could lead to errors in volume measurement.⁸ This issue is more problematic when the muscle volume cannot be obtained using a single sweep, as is the case for most of the main lower limb muscles. Thus, muscle volume acquisitions using 3DUS are currently done in a water tank.⁶ Although scanning in a water tank is feasible for the distal muscles such as the plantar flexors, it is much more complicated for proximal muscles of the leg, trunk, or arm. This strongly limits the clinical applicability of 3DUS. Cenni et al⁹ recently proposed an innovative solution by adding a gel pad to the transducer with a shape that fits the curvature of the lower leg. This method significantly decreased muscle deformation compared to a scan

performed without the gel pad but left room for improvement because the pressure applied could not be constant during the multiple sweeps.

To help the 3DUS acquisition, we designed a larger contoured gel pad that fits to the whole lower leg to scan a flat surface and distribute the pressure of the transducer more homogeneously. The aim of this study was to compare gastrocnemius medialis (GM) muscle volume obtained by 3DUS using this customized gel pad and measurements performed in a water tank.

Materials and Methods

Participants

Sixteen healthy participants volunteered for this study. The study protocol and procedures were approved by the local Ethics Committee (Rennes Ouest V, CPP-MIP-010). Informed consent for the study was obtained from all participants, in accordance with the World Medical Association Declaration of Helsinki (2013).

Gel Pad Design

We used a single mold to make a gel pad that could fit all of our participants (Figure 1A). Stereolithography (3D printing; 3DExperience; Dassault Systèmes, Vélizy-Villacoublay, France) was chosen to obtain a smooth internal surface for the mold. The mold was made in a thermoplastic polymer called acrylonitrile butadiene styrene. Three-dimensional plans were drawn with Solidworks software (Dassault Systèmes). The pad was made with 2.7 L of distilled water, 675 g of porcine gelatin (Bloom Louis François, Croissy Beaubourg,

France), 5.94 g of chlorphenesin, and petroleum jelly to facilitate demolding. One gel pad was used for the whole data collection in this study.

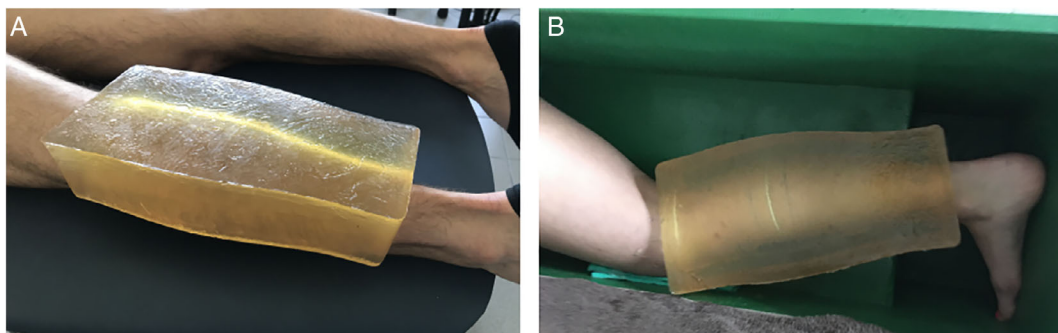
Three-Dimensional US Acquisitions

The method used to perform 3DUS acquisitions was previously described in detail.^{1,3,5-9} Briefly, images were recorded with an Aixplorer version 12.3 scanner (SuperSonic Imagine, Aix-en-Provence, France) equipped with a 10–2 linear transducer (40-mm field of view; Vermon, Tours, France). The position and orientation of the US transducer were measured with 4 reflective passive markers rigidly fixed to the transducer surface. This “rigid body” was tracked by an optoelectrical motion capture system (Optitrack; NaturalPoint, Corvallis, OR) with 9 cameras (Flex 13). Temporal and spatial calibrations of the transducer were established in a water tank according to recommendations from the Stradwin version 5.4 software manual¹⁰ (Mechanical Engineering, Cambridge University, Cambridge, England). It consists of tracking the bottom of the tank to account for both the temporal gap between US and 3D motion capture and calculating the 3D position of the US image. The root mean square error obtained during the calibration process was consistently lower than 0.4 mm. It evaluates the error between a pixel localized in a B-scan coordinate system and its corresponding location in the volume coordinate system obtained.¹¹

Three-Dimensional US Protocol

Scanning was performed by a single operator that had no previous experience with US. He did a long

Figure 1. A, Gel pad placed on the lower leg of a participant. **B,** Positioning of the participant for the 3DUS-gel pad condition with the gel pad sitting on the right leg of a participant positioned in the tank. The 3DUS-water condition was performed in the same position but with water in the tank.



training session (>50 hours) and numerous pilots to ensure good reliability. Participants underwent 2 identical sessions on 2 separate days within a week. Anatomic landmarks were determined by 2-dimensional B-mode US to identify proximal and distal boundaries for the scanning. Proximally, the most superficial aspect of the inferior margin of the medial tibial condyle was chosen and distally, the GM musculotendinous junction.¹² A thin band of adhesive tape was then set on the proximal landmark to be seen on US images.

For the reference condition, 3DUS-water, the right leg of the participants was placed in a water tank in a resting kneeling position, as previously described.⁶ For the 3DUS-gel condition, participants were in the same position but without water, and the gel pad was fitted on their test leg (Figure 1B). Coupling gel was added between the gel pad and the skin and on the gel pad surface to enable a steady sliding scan procedure during each sweep. The position of the thigh was standardized between conditions with an inclinometer. For practical reasons, the condition order was not randomized, and the 3DUS-gel measurements were always performed before the 3DUS-water measurement.

Three 3DUS acquisitions were performed for each condition. A sweep consisted of moving the transducer to scan the GM muscle from the proximal to the distal boundaries. Between 3 and 5 sweeps were performed for each acquisition, depending on the size of the GM muscle of each participant. An overlap of approximately 0.5 cm was implemented to prevent any gap between the different sweeps and to save time during data processing.⁷ At the end of each acquisition, the absence of gaps was checked.

Data Analysis

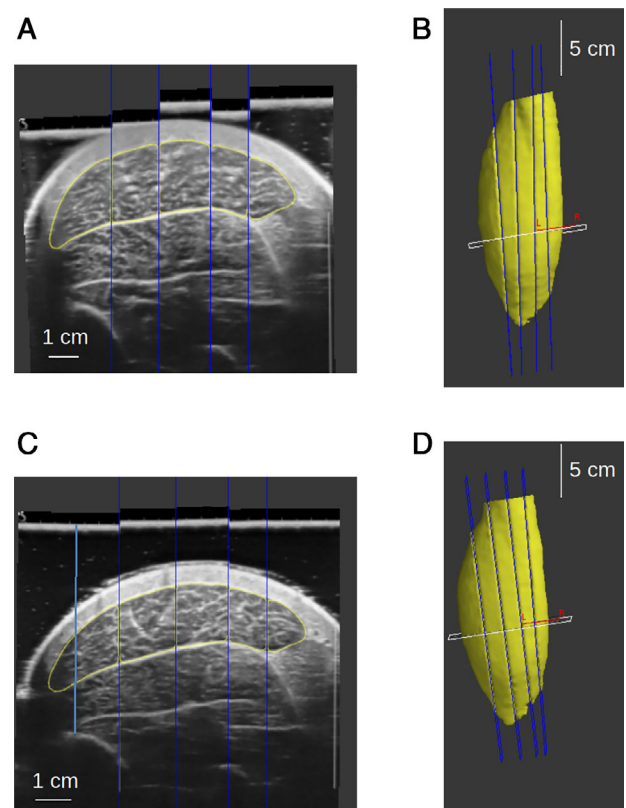
Stradwin software was used for the manual segmentation of the GM muscle, which was undertaken every 10 images (approximately every 0.5 cm) by a single experimenter (Figure 2) who was experienced in the segmentation process.⁸ Specific data volume results for each participant were compiled only at the end of the study to avoid any rater analysis effect. Interrater reliability of the segmentation process was evaluated by a second trained experimenter on 10 participants randomly chosen in session 1. On the basis of a model published by Treece et al,¹³ the Stradwin software transformed the segmented cross-sectional areas

in a smoothed model to obtain the GM shape and corresponding volume.

Statistical Analysis

The validity of the experimental technique versus the reference method was assessed by Bland–Altman analyses¹⁴ and the 95% the limit of agreement. Intrasession, intersession, and interoperator reliability of the 3D scanning process were assessed for both gel pad and water conditions by intraclass correlation coefficients, coefficients of variation (CVs), and the standard error of measurements (SEM).¹⁵ The minimum detectable change was also calculated as $SEM \times \sqrt{2} \times 1.96$.

Figure 2. **A**, Typical segmentation performed for the 3DUS-water method. **B**, Three-dimensional reconstruction obtained at the end of the processing. **C**, Typical segmentation performed for the 3DUS-gel pad method. **D**, Three-dimensional reconstruction obtained at the end of the processing. For this participant, the muscle volumes were 299.7 and 293.0 mL for the 3DUS-water and 3DUS-gel pad methods, respectively. Note that the B-mode image quality was slightly better in the 3DUS-gel pad condition, and the segmentation was slightly easier. Blue lines represent the image borders of the successive sweeps.



Results

The 16 participants included 5 women and 11 men (mean age \pm SD, 22.7 ± 1.5 years; body weight, 68.9 ± 6.9 kg; and height, 175.6 ± 6.4 cm).

Validity

With the 3 measurements for each condition, the volume obtained in the 3DUS-water condition was 221.9 ± 36.4 mL versus 218.6 ± 36.2 mL for the

3DUS-gel condition (Table 1). The mean bias between the methods was 3.4 ± 3.9 mL with a limit of agreement of 7.7 mL. Bias was significant, with a 95% confidence interval of 2.1 mL (Figure 3A). It revealed a small underestimation of the GM muscle volume for the 3DUS-gel versus 3DUS-water condition. Validity was also assessed with only the first acquisition (trial) of each condition, and this showed a bias of 2.7 ± 4.4 mL with a limit of agreement of 8.7 mL (Table 1 and Figure 3B). It was indicative of

Table 1. Validity: Comparison of GM Muscle Volume (Bland–Altman Analysis) Between 3DUS-Water and 3DUS-Gel

Parameter	3DUS-Water, mL	3DUS-Gel, mL	Bias, mL	LoA, mL	Bias, %	LoA, %	CI, mL
3 scans	221.9 ± 36.4	218.6 ± 36.2	3.4 ± 3.9	7.7	1.5 ± 1.7	3.4	2.1
1 scan	221.7 ± 36.1	219.0 ± 36.2	2.7 ± 4.4	8.7	1.3 ± 2.0	3.9	2.3

Data are presented as mean \pm SD where applicable. Bias indicates mean difference; CI, 95% confidence interval; LoA, 95% limit of agreement ± 2 SDs; 3 scans, mean of the 3 scans of a session; and 1 scan: first scan of the session.

Figure 3. Bland–Altman plots showing the differences between the 3DUS-gel and 3DUS-water methods. Data are the mean of the 3 scans of the first session (A) and only the first scan of the first session (B).

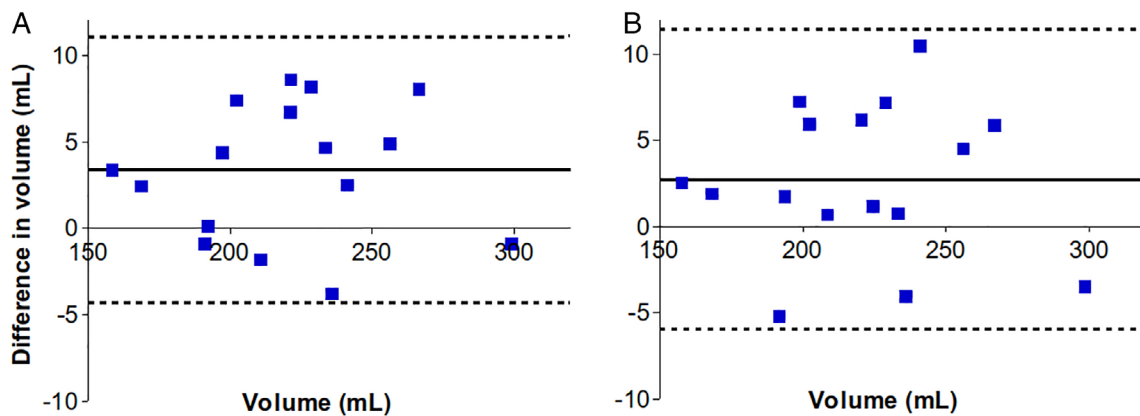


Table 2. Reliability of the 3DUS-Water and 3DUS-Gel Methods to Scan GM Muscle Volume

Parameter	3DUS-Water				3DUS-Gel			
	ICC	CV, %	SEM, mL	MDC, mL	ICC	CV, %	SEM, mL	MDC, mL
Intersession								
3 scans	1.00	1.1	2.6	7.1	0.99	1.6	3.3	9.3
1 scan	0.99	1.3	3.0	8.4	0.99	1.9	4.0	11.0
Intrasession								
3 \times 1 scan	1.00	1.0	2.3	6.2	1.00	1.0	2.3	6.4
Interrater								
3 scans	1.00	0.7	1.5	4.2	1.00	0.7	1.5	4.2
1 scan	1.00	1.1	2.4	6.5	1.00	1.1	2.2	6.0

ICC indicates intraclass correlation coefficient; and MDC, minimal detectable change.

a similar underestimation of the volume when using the gel pad with only a single acquisition compared to 3 scans.

Reliability

Overall, the reliability of the volume measurements was excellent (intraclass correlation coefficient, >0.99 for all conditions; Table 2). For the intrasession reliability, the CV and SEM were 1.0% and 2.3 mL, respectively, regardless of the method. For the between-day reliability, the CV and SEM were low for both the 3DUS-water condition (CV, 1.1%; SEM, 2.6 mL) and the 3DUS-gel condition (CV, 1.6%; SEM, 3.3 mL). For both methods, the 3 measurements only marginally improved the intersession reliability. The interrater reliability was also excellent, with very similar results for both methods (3 measurements, CV, 0.7%; SEM, 1.5 mL; 1 measurement, CV, 1.1%; SEM, 2.3 mL).

Discussion

This study shows that the use of a gel pad is a reliable and valid alternative to the water tank protocol for measuring the GM muscle volume using 3DUS. The reliability analysis showed values that were similar to the literature. Barber et al⁵ obtained CVs of 3.4% and 6.6% for intrasession and interrater reliability, respectively, on the GM muscle of children. Cenni et al⁸ also measured the GM muscle volume of healthy children and children with cerebral palsy. They reported SEMs for intrasession reliability of 1.9 and 1.7 mL and for interrater reliability of 1.2 and 1.4 mL in these groups. Mean volumes of the GM muscle were notably smaller in the children: approximately 50 mL for both of these studies compared to our adult participants. This finding provides an explanation for the higher CV values in these studies compared to our study. To our knowledge, intersession reliability for 3DUS was not previously described in the literature.

In this study, a small but significant underestimation was found for the 3DUS-gel method versus 3DUS-water method (≈ 3 mL [1.4%]). This finding is in the same range as those reported for volume measurements using the 3DUS-water method compared to computed tomography and MRI. Thus, Barber et al⁵ reported a nonsignificant bias of approximately 2 mL for GM muscle volume measured by the 3DUS water tank method versus MRI. However, the limit of agreement (≈ 18 mL) was much

higher than in our study (≈ 8 mL). Therefore, it could be hypothesized that the 3DUS-gel method would present no underestimation compared to MRI, which remains the reference standard for muscle volume measurements. In addition, Cenni et al⁹ found a difference of 2.3 mL (2.8%) between a method that used a gel pad transducer to reduce soft tissue deformation and the water tank method.

A limitation of this study was that the whole muscle volume was not scanned. We used the most superficial aspect of the inferior margin of the medial tibial condyle as the proximal boundary of the muscle. This landmark leads to an underestimation of the actual GM muscle volume with an underestimation of $11.8\% \pm 2.8\%$ compared to the whole GM muscle volume.¹² However, the rationale for our boundary was principally a “trade-off” situation to achieve our aim of scanning in the same anatomic position in both conditions. Although the gel pad could not be placed more proximal, because of the flexed knee position, if we had used an extended knee, we could not have scanned in the water without having the participant lying prone in a pool, which was not feasible. The small but significant underestimation found when using the gel pad could in part have been due to proximal GM muscle deformation that shifted part of the muscle to the zone that was not measured. Additionally, it has been reported that in the proximal zone, muscle boundaries can appear unclear and induce higher variability in measurements.¹² In several cases during this study, we observed that muscle boundaries were easier to see when using the gel pad compared to the water tank (Figure 2).

We acknowledge that our gel pad probably induced a global pressure and an initial deformation to the muscle scanned. This is the probable explanation for the volume underestimation with our method because the whole muscle was not scanned (see previous paragraph). However, this deformation was constant during the scanning and should not bias the volume measurement of a whole muscle, since the muscle can be considered isovolumic. Our gel pad enables the experimenter to apply very limited pressure during a sweep and between sweeps. This is because the surface of the gel pad is flat, which limits the influence of longitudinal (within a sweep) and transverse (between sweeps) changes in shape of the calf due to the pressure applied with the transducer.

It was not the case with the gel pad developed by Cenni et al,⁹ which reduced the muscle deformation by about 46%. For all these reasons, we are convinced that our gel pad method is currently the best solution to minimize the artifacts due to transducer compression during sweeps using freehand 3DUS scanning.

Interestingly, from a resource perspective, the same pad was satisfactorily used for all the participants despite a wide range of muscle volumes that were measured (160–299 mL). Furthermore, compared to water, operators using the gel pad for scanning anecdotally reported that it was easier to perform the required movements of the transducer with the presence of the flat scanning surface that can be used to visualize the previous sweeps with the mark created by the US coupling gel.

In conclusion, across a number of statistical parameters, the gel pad technique was shown to be a valid and reliable method to assess GM muscle volume. The method does not require the leg to be placed in water, which is more comfortable for the participant and examiner. It also does not require the presence of a relatively large tank that must be filled and cleaned thoroughly after each session with a participant. Finally, operators found the gel pad technique easier to perform, and data collection times for each participant were notably shorter when using the gel pad. Overall, this study addresses a methodological gap in volumetric measurements of muscles that will affect the understanding of muscle disorders in which atrophy is a main symptom (eg, Duchenne muscular dystrophy and cerebral palsy).

References

1. Barber L, Hastings-Ison T, Baker R, Kerr Graham H, Barrett R, Lichtwark G. The effects of botulinum toxin injection frequency on calf muscle growth in young children with spastic cerebral palsy: a 12-month prospective study. *J Child Orthop* 2013; 7:425–433.
2. Barrett RS, Lichtwark GA. Gross muscle morphology and structure in spastic cerebral palsy: a systematic review. *Dev Med Child Neurol* 2010; 52:794–804.
3. McNee AE, Gough M, Morrissey MC, Shortland AP. Increases in muscle volume after plantar flexor strength training in children with spastic cerebral palsy. *Dev Med Child Neurol* 2009; 51:429–435.
4. Mitsiopoulos N, Baumgartner RN, Heymsfield SB, Lyons W, Gallagher D, Ross R. Cadaver validation of skeletal muscle measurement by magnetic resonance imaging and computerized tomography. *J Appl Physiol* 1998; 85:115–122.
5. Barber L, Alexander C, Shipman P, Boyd R, Reid S, Elliott C. Validity and reliability of a freehand 3D ultrasound system for the determination of triceps surae muscle volume in children with cerebral palsy. *J Anat* 2019; 234:384–391.
6. Barber L, Barrett R, Lichtwark G. Validation of a freehand 3D ultrasound system for morphological measures of the medial gastrocnemius muscle. *J Biomech* 2009; 42:1313–1319.
7. Weide G, van der Zwaard S, Huijting PA, Jaspers RT, Harlaar J. 3D ultrasound imaging: fast and cost-effective morphometry of musculoskeletal tissue. *J Vis Exp* 2017; 55943(129).
8. Cenni F, Schless SH, Bar-On D, et al. Reliability of a clinical 3D freehand ultrasound technique: analyses on healthy and pathological muscles. *Comput Methods Programs Biomed* 2018; 156:97–103.
9. Cenni F, Schless SH, Monari D, et al. An innovative solution to reduce muscle deformation during ultrasonography data collection. *J Biomech* 2018; 77:194–200.
10. Hsu PW, Prager RW, Gee AH, Treece GM. Rapid, easy and reliable calibration for freehand 3D ultrasound. *Ultrasound Med Biol* 2006; 32:823–835.
11. Dong J, Cong W, Ai D, et al. Multiresolution cube propagation for 3-D ultrasound image reconstruction. *IEEE Trans Comput Imaging* 2019; 5:25.
12. Noorkoiv D, Marika Theis N, Lavelle G. A comparison of 3D ultrasound to MRI for the measurement and estimation of gastrocnemius muscle volume in adults and young people with and without cerebral palsy. *Clin Anat* 2019; 32:319–327.
13. Treece GM, Prager RW, Gee AH, Berman L. Surface interpolation from sparse cross sections using region correspondence. *IEEE Trans Med Imaging* 2000; 19:1106–1114.
14. Bland JM, Altman DG. Statistical methods for assessing agreement between two methods of clinical measurement. *Lancet* 1986; 1:307–310.
15. Hopkins WG. Measures of reliability in sports medicine and science. *Sports Med* 2000; 30:1–15.